Keratoconus Update

Diagnosis of Keratoconus

Sheraz Daya
MD FACP FRCS(Ed) FRCOphth

CENTRE FOR SIGHT

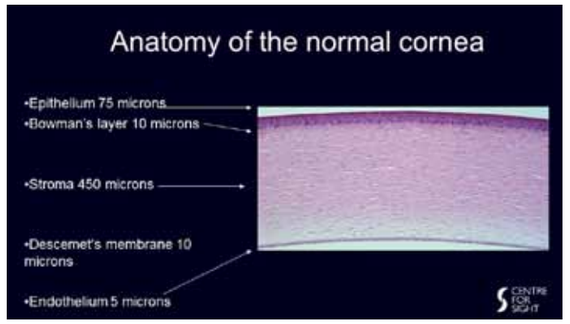

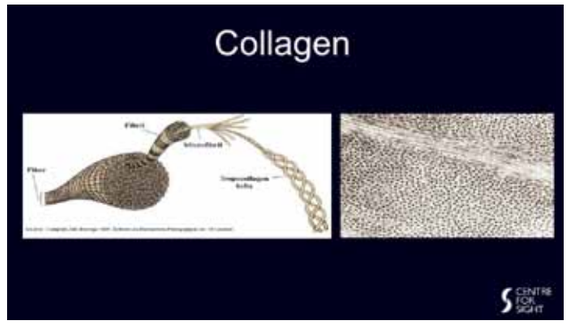

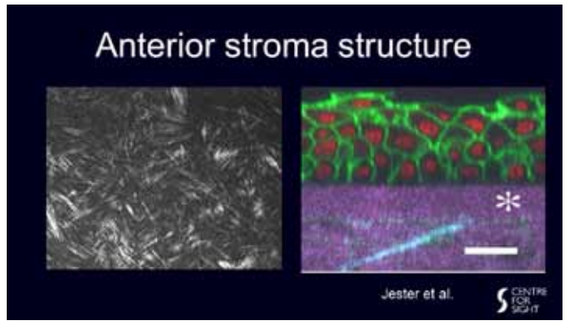

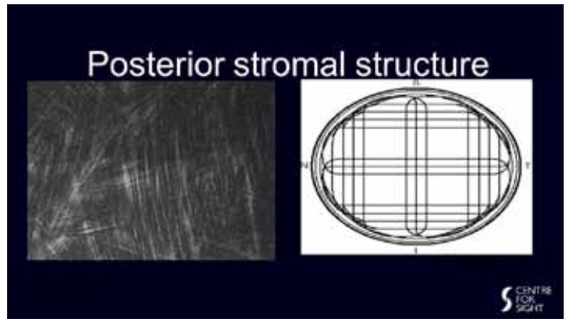

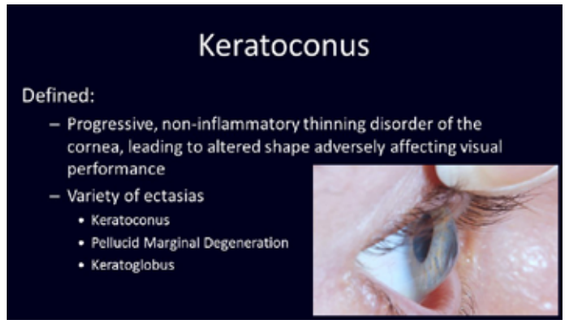

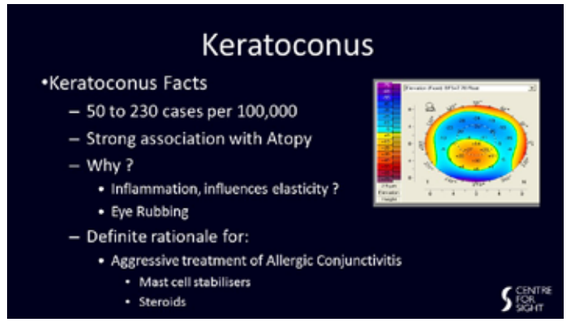

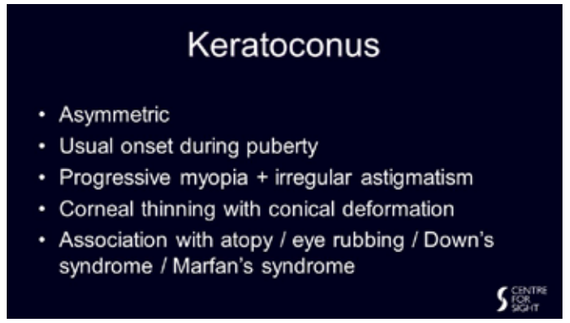

'Diagnosis of Keratoconus'
(slides 1-8)

Sheraz Daya
MD FACP FRCS(Ed) FRCOphth

Keratoconus

- Epithelial thinning
- Fragmentation of Bowmans
- Apical scarring
- Fleischer ring
- Stromal thinning
- Posterior stromal / Descemet's folds (Vogt's)
- Descemet's tear - hydrops

KERATOCONUS - Pathogenesis

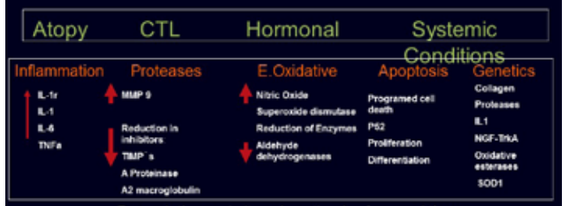

Degradation and altered synthesis of corneal tissue

Courtesy Jesus Merayo, Oviedo, Spain

Balance of Degradation vs Regeneration

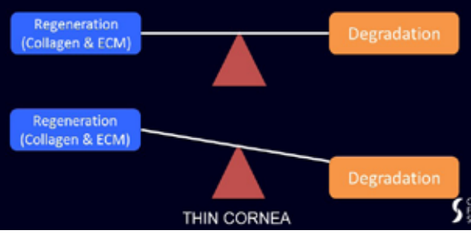

Diagnosis



- Clinical
- Topographic
  - Pentacam – more sensitive and specific
    - Belin-Ambrosio
- Corneal Hysteresis
  - Newer technology in development

Keratoconus

- CLINICAL
  - Astigmatism – increasing
  - Retinoscopy/ retroillumination
    - Droplet appearance – red reflex
    - Scissoring
  - Munson Sign

Rizzuti's Sign

DIAGNOSIS - Clinical

Keratoconus
- Thinning
- Apical scarring
- Vogt's striae

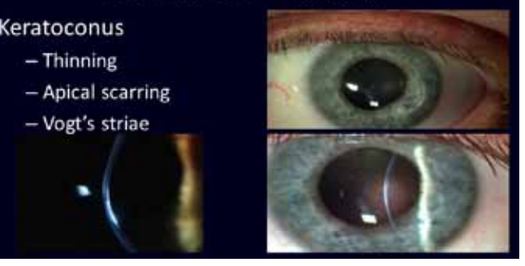

DIAGNOSIS - Clinical

Fleischer Ring

Vogt's Striae

Hydrops

Pellucid Marginal Degeneration

Keratoglobus

DIAGNOSIS: Corneal Topography

- Steep cornea
- Non- orthogonal astigmatism
- Inferior Steepening
- Coinciding point:
  - Anterior elevation
  - Posterior elevation
  - Thinnest spot on cornea

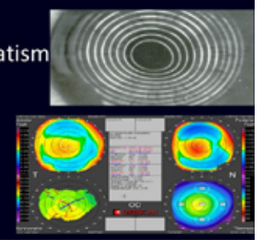

Keratoconus

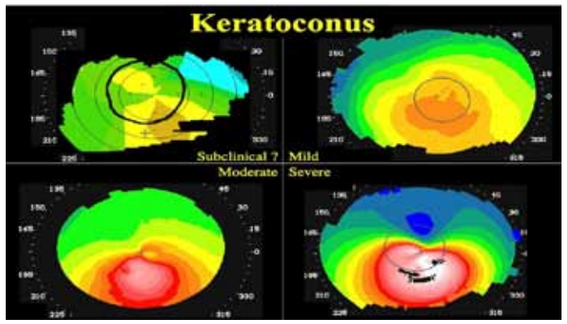

3-Dimensional Topography

- Slit beam – Orbscan
- Scheimpflug – Pentacam, Gallilei, Sirius

Scanning slits measure several surfaces

'Diagnosis of Keratoconus'

(slides 9-24)

Sheraz Daya
MD FACP FRCS(Ed) FRCOphth

CENTRE FOR SIGHT

Scheimpflug imaging

- Pentacam (Oculus, Inc)
- Two integrated cameras:
  - Central: size and orientation of the pupil, and fixation
  - Rotating Scheimpflug camera
- 50 Scheimpflug images during one scan in less than 2 seconds

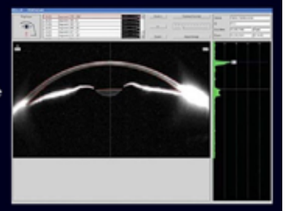

The Pentacam analyses complete anterior segment

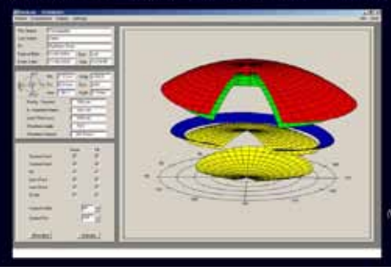

(Courtesy of Oculus, Inc.)

Scheimpflug imaging

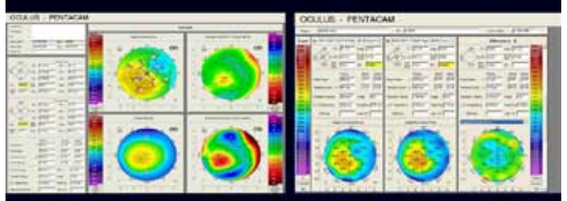

Ultrasound digital topography

- High-frequency ultrasound scanning
- Thickness of corneal layers with high precision.
- Post refractive surgery.
- Not limited to optically transparent tissue.

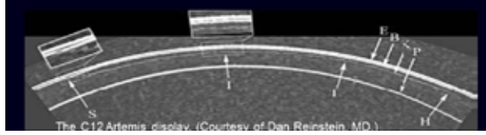

The C12 Artemis display. (Courtesy of Dan Reinstein, MD.)

Corneal Biomechanics



Ocular Response Analyzer Measurement Signal

CORVIS - Corneal Deformation

KERATOCONUS

Deforms earlier
Increased
- Deformation
- Oscillation

Courtesy Renato Ambrosio

Keratoconus Diagnosis

- Clinical
  - Oblique or ATR astigmatism
  - Increasing astigmatism
  - Scissoring
- Diagnostics
  - 3-D tomography – gold standard
  - Hysteresis - useful

Treatment options

- TRADITIONAL
- Spectacles
- Contact lenses
  - Soft ; toric; RGP;
- Corneal graft
  - Penetrating keratoplasty
  - Lamellar keratoplasty

Management of Keratoconus

- Collagen Crosslinking (CXL)
  - +/- topo guided PRK
- Intracorneal Rings
- Myoring
- Toric Phakic Lenses (ICL or Artisan)
- Corneal Transplantation

‘Diagnosis of Keratoconus’

(slides 25-33)

Sheraz Daya
MD FACP FRCS(Ed) FRCOphth

CENTRE FOR SIGHT

Keratoconus Update

Corneal Collagen CrossLinking

Marcela Espinosa
MD

CENTRE FOR SIGHT

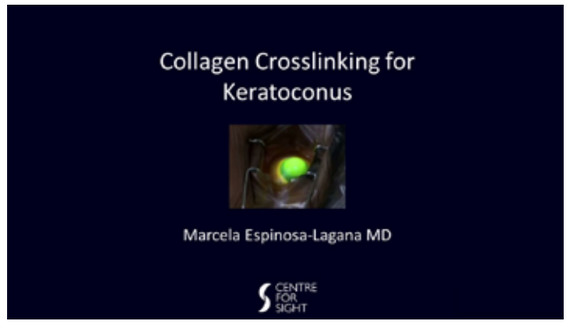

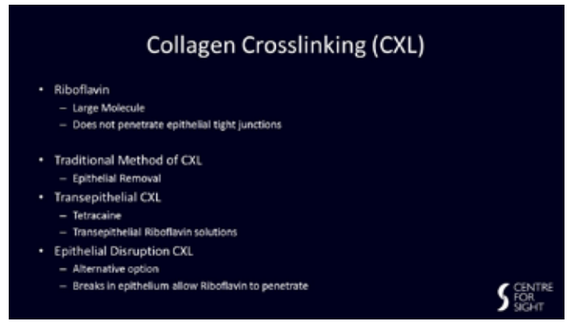

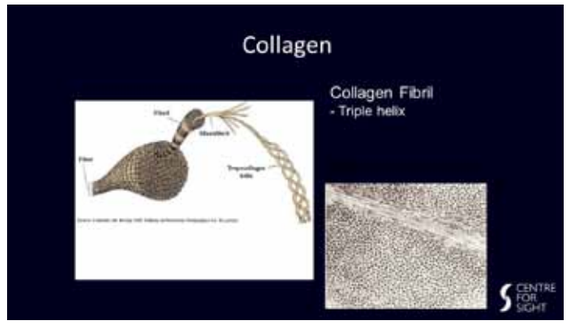

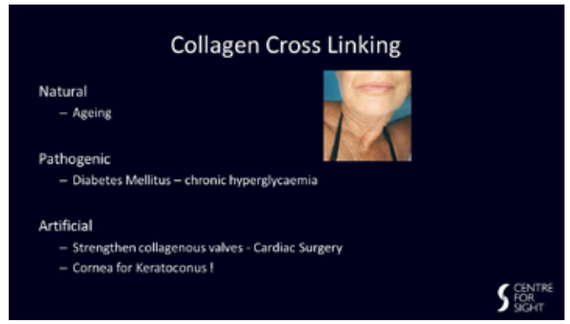

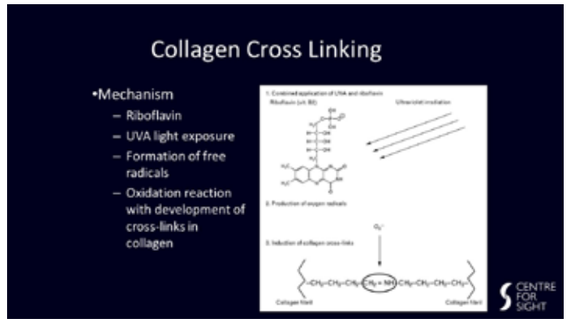

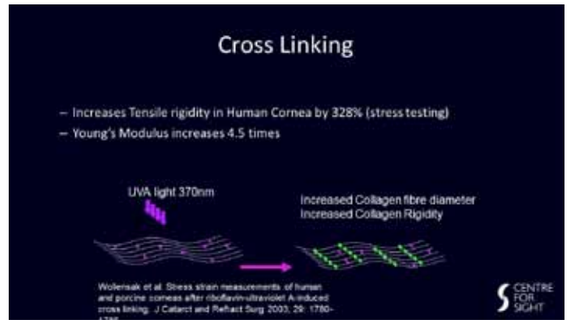

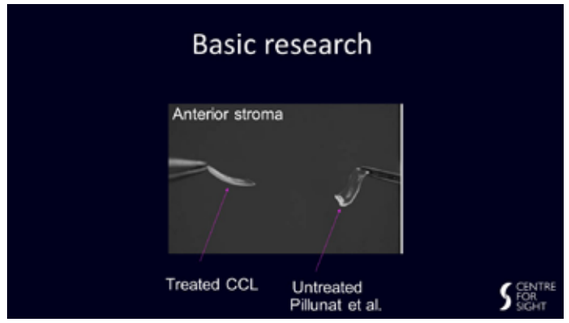

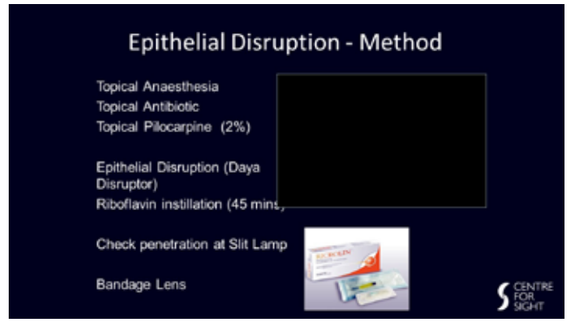

'Corneal Collagen CrossLinking'

(slides 1-8)

Marcela Espinosa
MD

Corneal "Cross linking"

UV light exposure (370nm)
3mW/cm2
Variable aperture
30 minutes

RESULTS

Bandage CTL – removed by 48 hours

Persistent Epithelial Defect	0
Infectious Keratitis	0
Sterile Infiltrates	0
Pain – day of procedure	111

Demarcation line or Anterior Haze 61%

Safety

Corneal thickness must be 400µm

If thinner use riboflavin without dextran

Measure before treatment!



Endothelium is reduced by 10% at week/after

Postop CXL – 1 month

Post op care

- Levofloxacin & Voltarol
- Bandage contact lens 24 – 48 hours
- Topical antibiotic 1 week

CXL – 1 month postop Demarcation

61%

Corneal "Cross Linking"

- Retrospective Study
- Keratoconus
- Analysis of Results Centre for Sight
- 111 Consecutive eyes 21/5/07 to 11/05/11

Cross Linking

- 111 Eyes. (72 patients with Keratoconus)
  - Single Centre – Retrospective study
  - 39 Bilateral
  - 49 RE 62 LE
  - 53 Male 18 Female
  - Mean age: 29.0 *(SD 9.2, Range 13.9-56.3)*

CXL Epithelial Disruption

VISUAL OUTCOMES

UCVA



UCVA Change

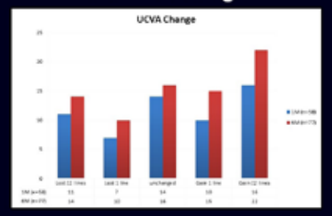

BCVA

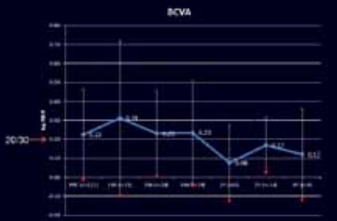

BCVA Change

Spherical Equivalent (M Refraction)

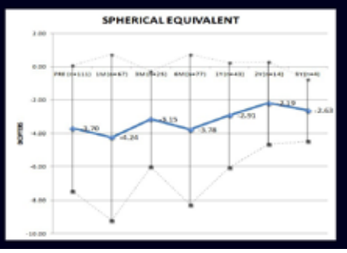

Astigmatism- Refractive

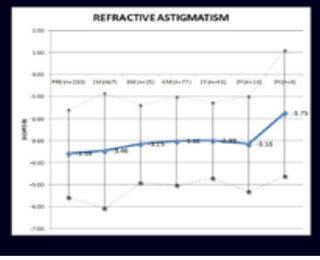

Keratometric Evolution (Pentacam)

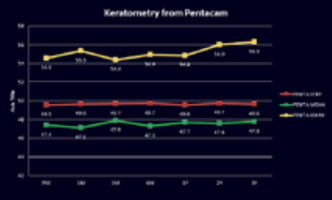

'Corneal Collagen CrossLinking'

(slides 9-24)

Marcela Espinosa
MD

CENTRE FOR SIGHT

Mean Keratometry (Pentacam)

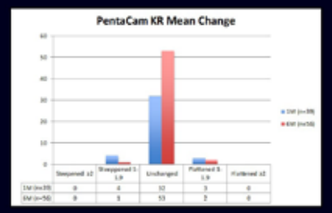

Steepest Keratometry (Pentacam)

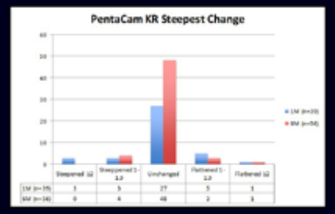

Kmax Evolution (Pentacam)

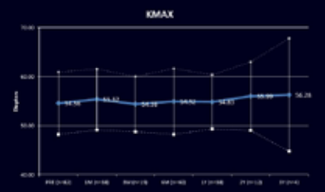

Kmax Change (Pentacam)

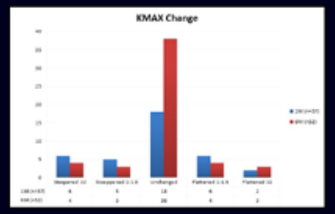

Pachymetry changes Pentacam / US



ED-CXL + Enhancers

- Prospective Study – *Rechichi et al, Italy*
- N=28
- Worst eye treated – Fellow eye Control
- ED-CXL & Riboflavin (EDTA & Trimetamol)
- Follow up – 12 months

Results

Refractive parameters

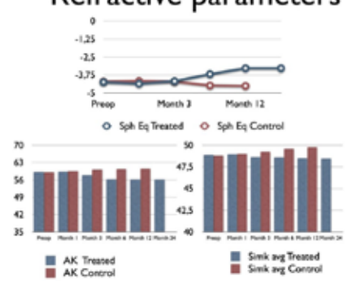

Conclusions

- Epithelial Disruption is an effective technique for CXL
  - Faster recovery
  - Less discomfort
- Kmean and Ksteep – no progression over 2 years
- Tendency to improvement on both UCVA and BSCVA
- Further and long term analysis is required

Thank you

‘Corneal Collagen CrossLinking’

(slides 25-34)

Marcela Espinosa
MD

Keratoconus Update

Intracorneal rings for Keratoconus

Sheraz Daya
MD FACP FRCS(Ed) FRCOphth

CENTRE FOR SIGHT

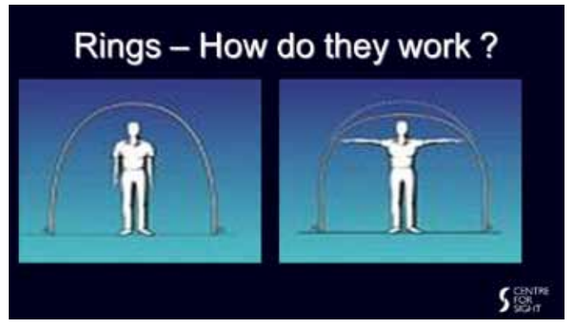

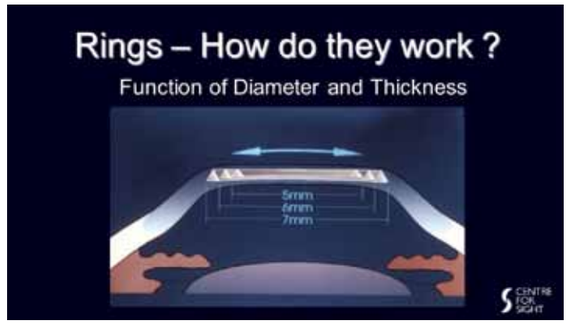

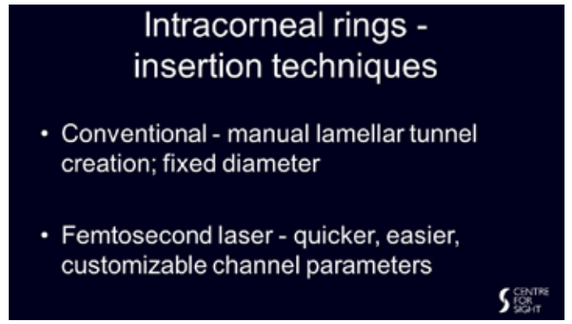

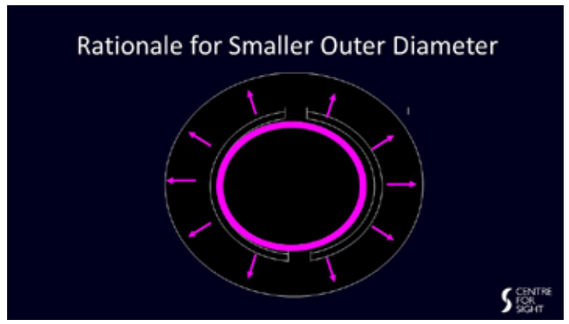

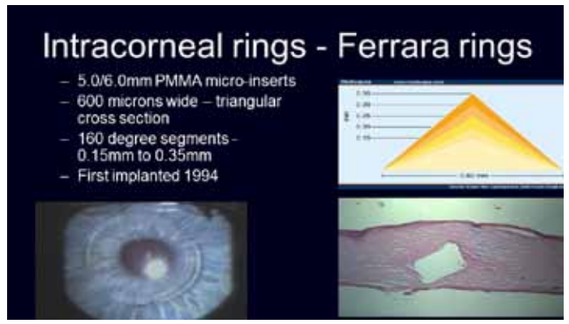

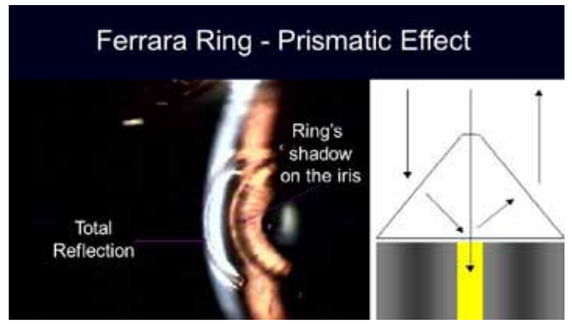

'Intracorneal Rings for Keratoconus'

(slides 1- 8)

Sheraz Daya
MD FACP FRCS(Ed) FRCOphth

Intracorneal rings - INTACS

- 7mm diameter PMMA micro-inserts
- 150 degree segments - 0.25mm to 0.45mm
- Hexagonal cross section
- Can treat corneas up to 55D



Intracorneal rings - INTACS SK

- Smaller - 6mm diameter PMMA micro-inserts
- - 0.40mm or 0.45mm
- For more severe cases – up to 62D
- Elliptical profile

Intracorneal rings - indications

- Spectacle / contact lens intolerance
- Keratometry up to 62D
- Clear visual axis
- Pachymetry > 400 microns

Intracorneal rings - indications

- MUST HAVE REALISTIC EXPECTATIONS
- Aim is to restore contact lens tolerance and improve BCVA - NOT UCVA
- Long recovery period - fluctuant vision for up to 18 months

Intracorneal rings - procedure

- Daycase / Topical anaesthesia
- Bandage contact lens for 24hrs
- Topical triple therapy for 1 month
  - G. chloramphenicol Q2H
  - G. levofloxacin Q2H
  - G. FML qds tapering by one drop weekly

Intralase Insertion of Intacs

INTACS - complications

- Infection
- Extrusion
- Perforation - mechanical > femto
- Channel deposits
- Inadequate effect - does not prevent treatment by corneal grafting

Infection

Infection



Extrusion

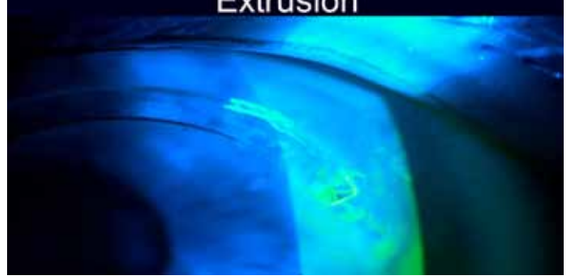

Channel deposits

Results - Change In Keratometry

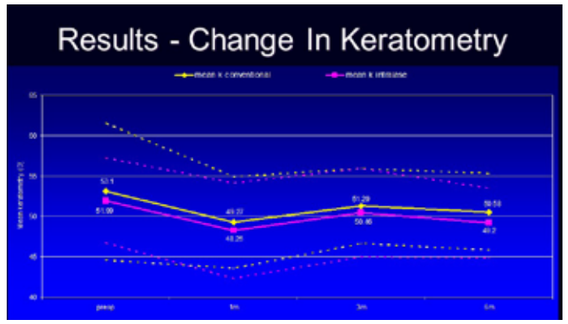

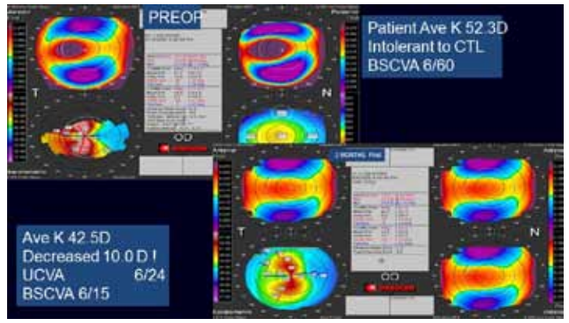

Results - Mean Refractive Cylinder

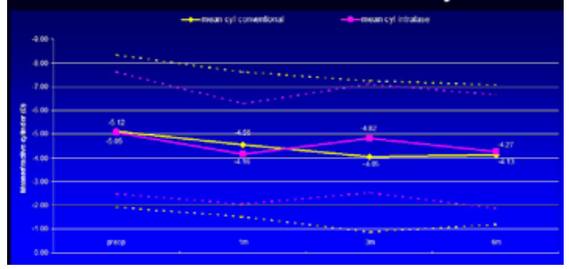

Results - Spherical Equivalent

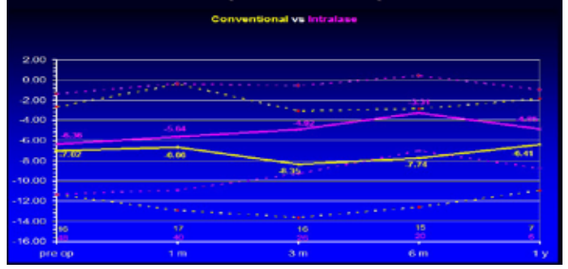

‘Intracorneal Rings for Keratoconus’

(slides 9-24)

Sheraz Daya
MD FACP FRCS(Ed) FRCOphth

CENTRE FOR SIGHT

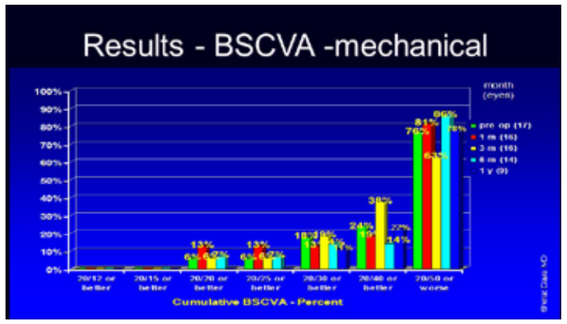

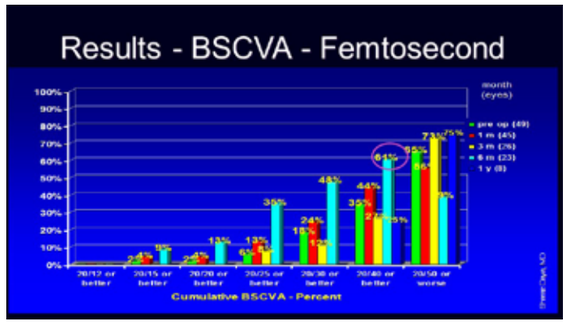

RESULTS - Ferrara literature

	BSCVA	MEAN KERATOMETRY	MEAN REF CYL	SPHERICAL EQUIV
PESANDO ET AL BJO 2010 100 EYES	Improved in 97.6%	Decreased by 4.56D		Decreased by 5.51D
FERRARA +TORQUETTI JCRS 2009 80 EYES	Improved in 86.4%	Decreased by 4.64D		Decreased by 2.96D
KWITKO/SEVERO JCRS 2004 51 EYES	Improved in 86.4%	Decreased by 5.59D	Decreased by 1.66D	Decreased by 1.53D
MIRANDA ET AL JRS 2003 36 EYES	Improved in 80.6%	Decreased by		Decreased by 2.49D

Results - INTACS literature

	BSCVA	MEAN KERATOMETRY	MEAN REF CYL	SPHERICAL EQUIV
SANSANAYUDH ET AL JCRS 2010 10 EYES - SK	Mean improved from -0.61 to -0.24 logmar	Decreased by 7.87D	Decreased by 1.15D	Decreased by 3.09D
RODRIGUEZ ET AL JRS 2003 7 EYES - SK	Improved in 86.4%	Decreased by 5.23D	Decreased by 1.66D	Decreased by 11.74D
WACHLER ET AL OPHTHALMOLOGY 2003 12 EYES	Improved in 45%			Decreased by 1.53D
J COLIN JCRS 2006 57 EYES	Improved by 2 lines or more in 63%	Decreased by 3.7D	Decreased by 2.94D	Decreased by 2.49D

Intracorneal rings - conclusions

One option in the armamentarium

Improve contact lens tolerance and BSCVA

Reduction in SE, Mean K & Astigmatism

Femtosecond better than mechanical

Intracorneal rings - conclusions

- Can be performed in conjunction with CXL
  - Early data
    - MORE effect
    - Less fluctuation
- Benefits of :
  - different arc lengths
  - Assymmetrical vs single vs double rings

Thank you !

‘Intracorneal Rings for Keratoconus’

(slides 25-31)

Sheraz Daya
MD FACP FRCS(Ed) FRCOphth

Keratoconus Update

Phakic Toric Lenses

Sheraz Daya
MD FACP FRCS(Ed) FRCOphth

CENTRE FOR SIGHT

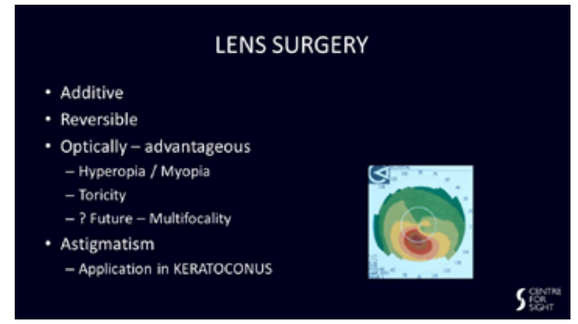

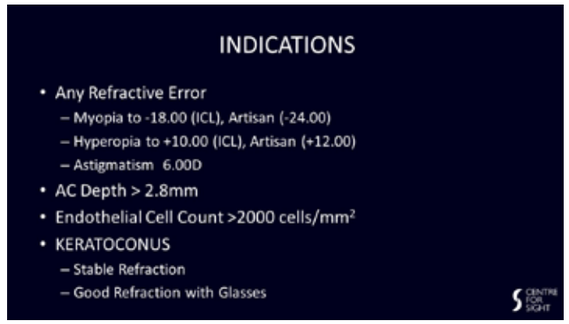

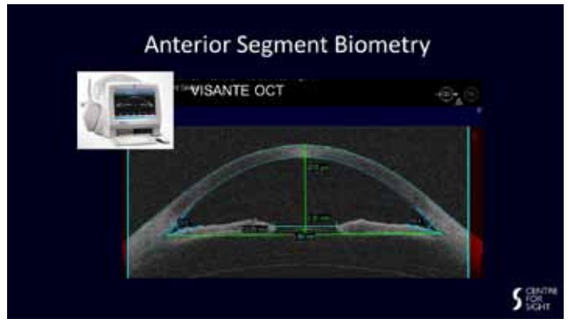

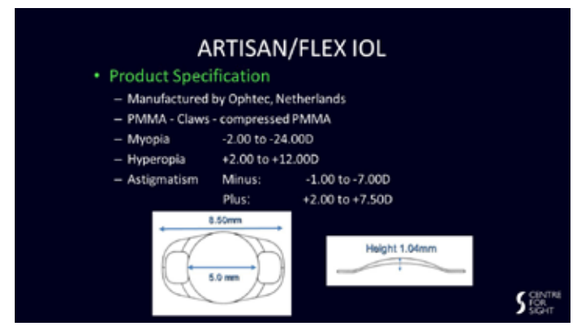

‘Phakic Toric Lenses’
(slides 1-8)

Sheraz Daya
MD FACP FRCS(Ed) FRCOphth

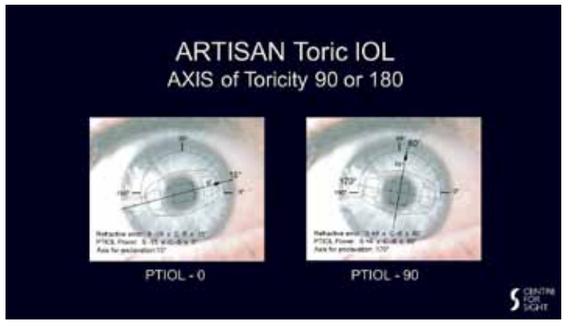



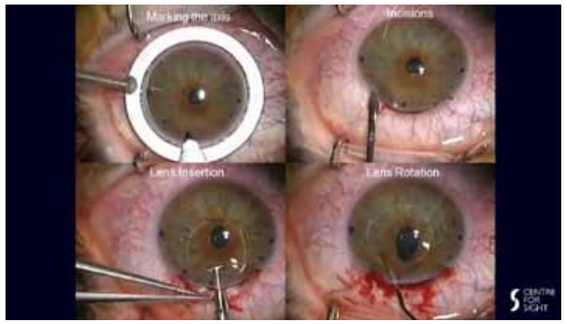

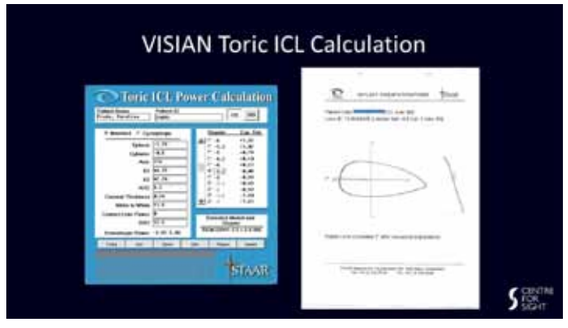

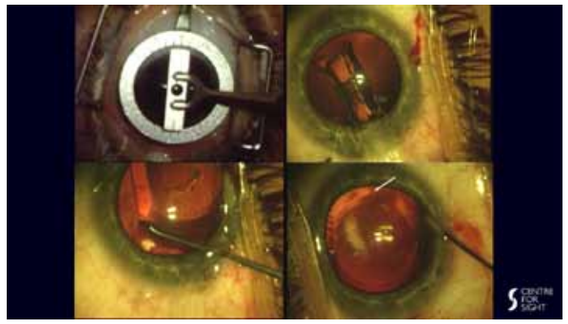

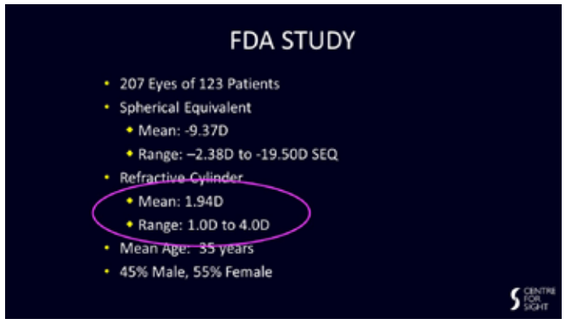

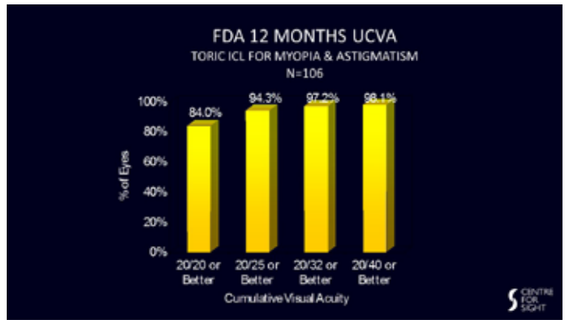

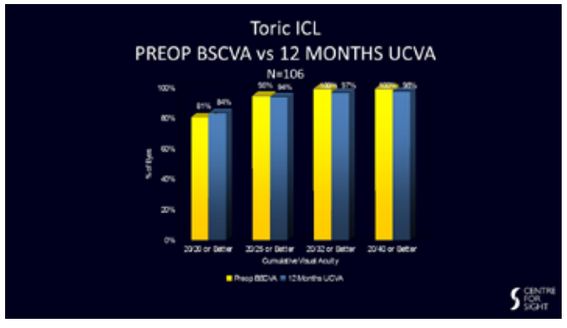

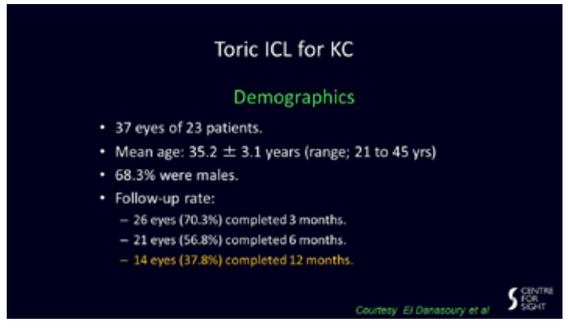

‘Phakic Toric Lenses’

(slides 9-24)

Sheraz Daya
MD FACP FRCS(Ed) FRCOphth

CENTRE FOR SIGHT

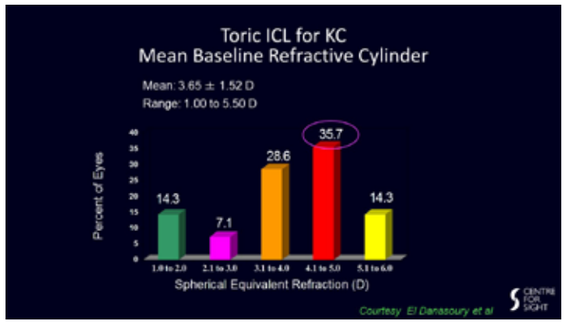

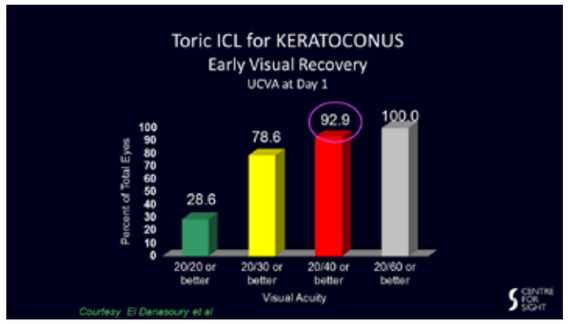





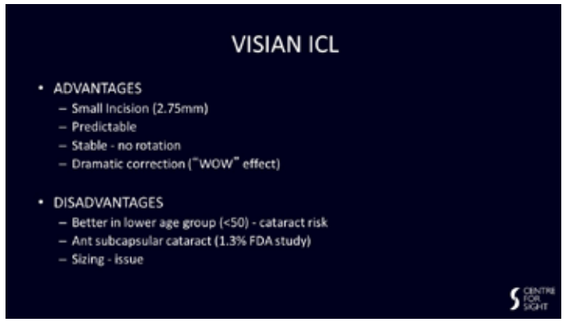

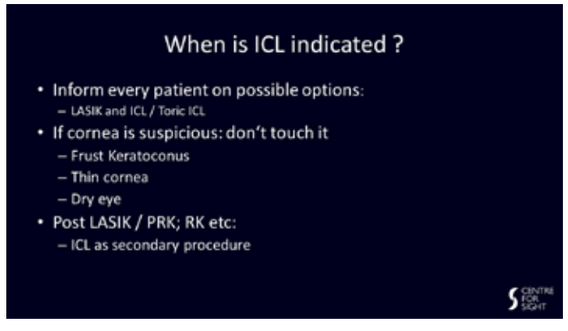

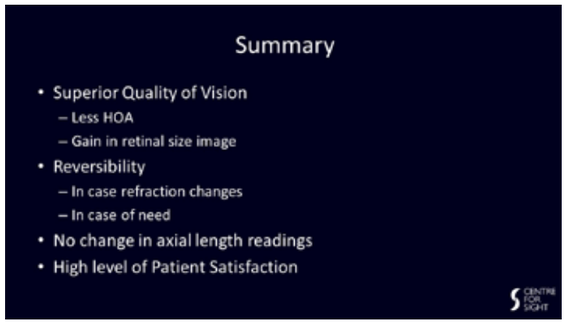

'Phakic Toric Lenses'

(slides 25-34)

Sheraz Daya
MD FACP FRCS(Ed) FRCOphth

CENTRE FOR SIGHT

Keratoconus Update

Keratoconus - An Algorithmic approach

Sheraz Daya
MD FACP FRCS(Ed) FRCOphth

CENTRE FOR SIGHT

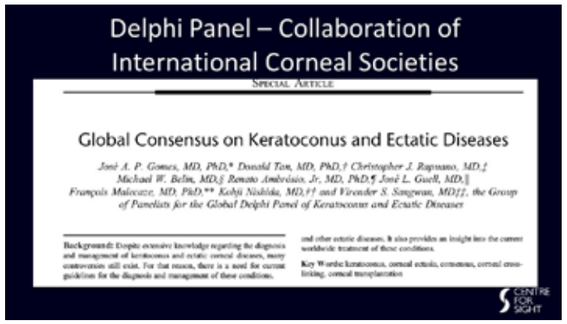

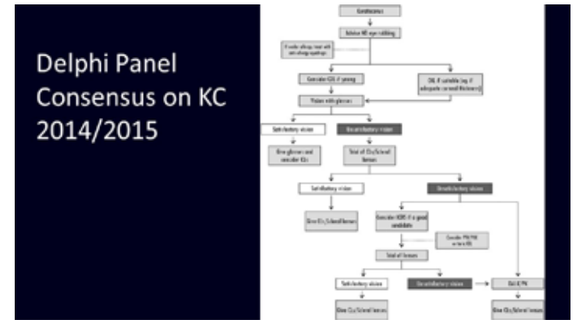

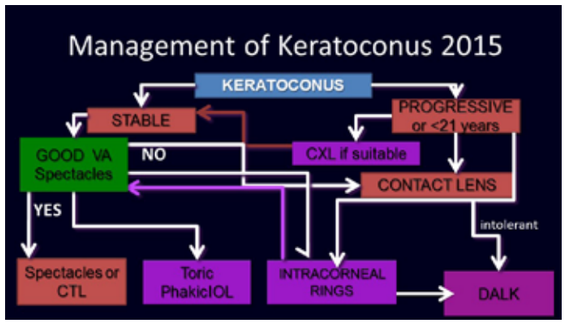

'Kertoconus - An Algorithmic approach'

(slides 1-7)

Sheraz Daya
MD FACP FRCS(Ed) FRCOphth