CORNEA 2002

celebrating 50 years of eye banking in the UK

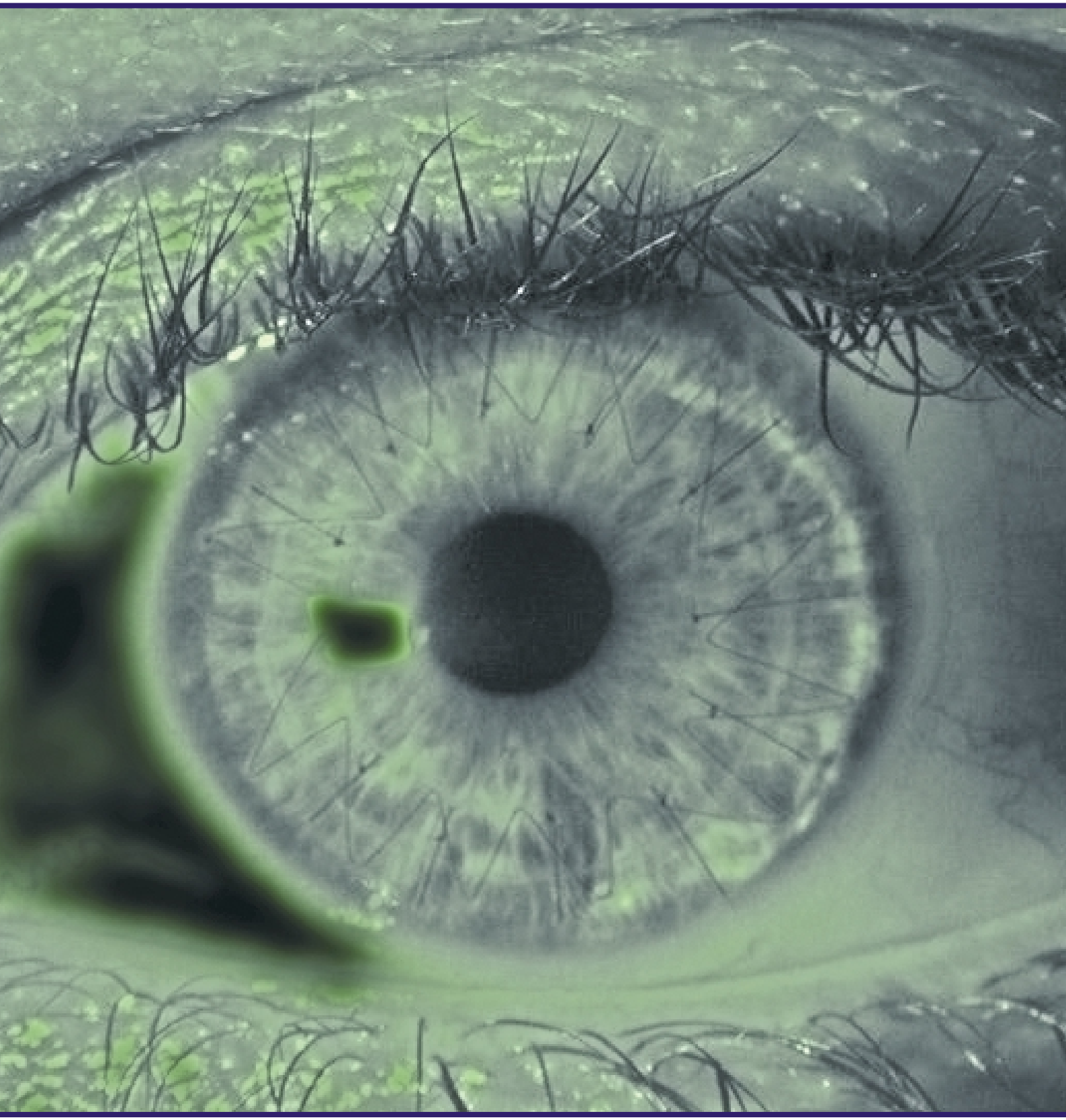

CORNEO PLASTIC UNIT AND EYE BANK

The Queen Victoria Hospital NHS
NHS Trust

centre for sight®

Thursday, 14 November, 2002
Friday, 15 November, 2002

WELCOME

Welcome to CORNEA 2002 – a celebratory event to mark 50 years of eye banking in the United Kingdom. The Corneal Grafting Act 1952, a private citizens bill was a reaction to the lack of legislation to permit donation of tissue for transplantation. Several newspaper articles in national and local newspapers raised public awareness and highlighted the need for appropriate legislation. Since then, eye banking has become organised in the UK and operates under the authority and support of UK Transplant. Supportive organizations like the European Eye Bank Association and the Eye Bank Association of America have made tremendous contributions to eye banking on respective sides of the Atlantic and worldwide.

We have a very tight and packed program which, in addition to providing us with insight into eye banking institutions, will also include current and controversial topics in Cornea. Ocular surface disease has made tremendous progress, with a variety of available procedures and techniques from Keratolimbal allografts through to ex-vivo stem cell expansion and amniotic membrane. With improved techniques, lamellar surgery has seen a resurgence with a variety of techniques available to accomplish the same goal. Deep lamellar endokeratoplasty is a novel approach for endothelial replacement that will certainly be part of the armamenterium in the future. Paediatric applications are an important and vital area. When all else fails keratoprosthesis is an option and again several methods will be discussed.

Refractive surgery continues to develop with applications in ametropic eyes following keratoplasty. Wavefront is currently in vogue with its own language and nomenclature holds much promise. While the majority of procedures involve the cornea, intraocular and combined techniques are becoming more acceptable and will also be discussed.

Finally, on behalf of the corneal community, I wish to express my tremendous gratitude to speakers who have taken the time to contribute and participate in this Conference. Many have travelled long distances at their own expense and we are very grateful. A personal thanks to David Paton who will be speaking at the celebratory dinner.

Thank you again for celebrating with us and I hope you have an enjoyable and highly educational conference.

CORNEA 2002

SPEAKERS & MODERATORS

W John Armitage, PhD,
Professorial Research Fellow in Tissue Biology and Transplantation,
Director of Tissue Banking, Division of Ophthalmology,
University of Bristol, UK.

Michaël Assouline, MD, PhD,
Ophthalmic Surgeon,
Practicien Titulaire, Fondation Ophtalmologique A de Rothschild,
Paris, France.

Michael W Belin, MD, FACS,
Professor of Ophthalmology,
Director – Cornea & Refractive Surgery,
Cornea Consultants of Albany, New York, USA.

Yean-Yaw Choong, MBBS(Mal), FRCS(Ed), Mmed(S'pore), AM(Mal),
Consultant Ophthalmic Surgeon, Sri Kota Refractive &
Eye Centre, Malaysia.
Visiting Cornea Surgeon to Hospital Kuala Lumpur, Malaysia.

Charles Claoué, MA(Cantab), MD, DO, FRCS, FRCOphth,
Consultant Ophthalmic Surgeon
specializing in Corneal and Refractive Surgery,
Consultant at Whipps Cross University Hospital, London, UK.
Medical Director at OptimEyes Laser Consultant, UK.

Patrick Condon, FRCS, FRCOphth,
Consultant Ophthalmic Surgeon,
Waterford Eye Clinic, Ireland.

John Dart, MA, DM, FRCS, FRCOphth,
Consultant Ophthalmologist,
Corneal External Disease and Cataract Services,
Moorfields Eye Hospital, UK.

Sheraz M Daya, MD, FACP, FACS, FRCS(Ed),
Director and Consultant Ophthalmic Surgeon,
Corneo-Plastic Unit and Eye Bank,
Queen Victoria Hospital, East Grinstead, UK.

Deepinder K Dhaliwal, MD,
Chief of Refractive Surgery and Assistant Professor in the Department of Ophthalmology, University of Pittsburgh School of Medicine, USA.

Claes H Dohlman, MD, PhD,
Professor of Ophthalmology,
Harvard Medical School, Boston, USA.

Harminder S Dua, MBBS, DO, DO(Lond), MS, MNAMS, FRCS, FRCOphth, MD, PhD,
Chair and Professor of Ophthalmology, University of Nottingham, UK.
Head of the Division of Ophthalmology and Visual Sciences, UK.

Marcela Espinosa, MD,
Co-Director of Research, Centre for Sight, East Grinstead, UK.

Celia R Hicks, BA, MB Bchir, MA, FRCOphth,
Research Surgeon and Clinical Trial Co-ordinator,
Artificial Cornea Programme, Lions Eye Institute,
Clinical Programme Manager, Argus Biomedical, Perth, Australia.

Edward J Holland, MD,
Professor of Clinical Ophthalmology,
University of Cincinnati, USA.
Director, Cornea Services, Cincinnati Eye Institute.

S Elizabeth James, PhD,
Senior Scientist, Wound Healing Group,
Blond McIndoe Centre, Queen Victoria Hospital, East Grinstead, UK.

Stephen S Lane, MD,
Clinical Professor of Ophthalmology,
University of Minnesota, USA.

Frank Larkin, MD, MRCPI, FRCOphth,
Consultant Ophthalmic Surgeon, Moorfields Eye Hospital
& Honorary Senior Research Fellow, Institute of Ophthalmology,
London, UK.

Christopher Liu, FRCOphth,
Consultant Ophthalmic Surgeon,
Sussex Eye Hospital, Brighton, UK.

Luca Ilari, MD,
Consultant Ophthalmic Surgeon, UK.

Mark J Mannis, MD, FACS,
Director: Cornea, External Disease and Refractive Surgery,
Vice-Chair, Department of Ophthalmology,
University of California, Davis, USA.

Jesús Merayo-Lloves, MD,
Consultant Ophthalmologist,
IOBA, University of Valladolid, Spain.

Erik L Mertens, MD,
Director and Ophthalmic Surgeon,
Antwerp Eye Centre, Belgium.

Kanwal Nischal, FRCS, FRCOphth,
Consultant Ophthalmic Surgeon, Great Ormond St Hospital for Children,
Fellowship Training Director,
Honorary Senior Lecturer, Institute for Child Health, London, UK.

Michael O'Keeffe, FRCS,
Newman Clinical Research Professor of Paediatric Ophthalmology,
Consultant Ophthalmic Surgeon,
Specialist in Paediatric & Refractive Surgery,
University College Dublin, Ireland.

Patricia Aiken O'Neill
President and CEO,
Eye Bank Association of America, USA.

James O'Reilly, FRCOphth,
Fellow in Cornea,
Corneo Plastic Unit & Eye Bank, Queen Victoria Hospital,
East Grinstead, UK.

Louis E Probst, MD,
Medical Director, TLCVision Inc.,
USA.

Chad K Rostron, MBBS, DO, FRCS, FRCOphth,
Consultant Ophthalmic Surgeon at Moorfields Eye Department,
St. George's Hospital, London
Honorary Senior Lecturer and Director of the Keratec Eye Bank,
St. George's Hospital Medical School, London, UK.

Gary S Schwartz, MD,
Comprehensive Ophthalmologist, Associated Eye Care,
Saint Paul, MN, USA.
Clinical Assistant Professor, University of Minnesota, USA.

Julian D Stevens, MRCP, FRCS, FRCOphth, DO,
Consultant Ophthalmic Surgeon,
Moorfields Eye Hospital, London, UK.

Mark A Terry, MD,
Director, Corneal Services, Devers Eye Institute,
Portland, Oregon, USA.

Andrew B Tullo, MD, FRCOphth,
Consultant Ophthalmic Surgeon and Honorary Senior Lecturer,
Manchester Royal Eye Hospital, UK.

David Verdier, MD
Associate Clinical Professor,
Michigan State University College of Human Medicine,
Grand Rapids, Michigan, USA.

Otto Wolter, MD,
Aruba Laser Refractive Institute,
Aruba, Dutch Caribbean.

Nada Al-Yousuf, MD, FRCSEd,
Consultant Ophthalmologist,
Ophthalmology Department,
Salmaniya Medical Complex, Kingdom of Bahrain.

Zbigniew F Zagórski, MD,
Professor of Ophthalmology,
Tadeusz Chair of Ophthalmology,
Medical University of Lublin, Poland.

THE CORNEAL TRANSPLANT NETWORK IN THE UK

W John Armitage, PhD, University of Bristol, UK

In the early 1980s, there were still only two eye banks in the UK at, respectively, the Queen Victoria Hospital in East Grinstead and Moorfields Eye Hospital, London. Elsewhere in the UK, surgeons typically had to rely on local eye donors, which resulted in long waiting times for patients, grafts having to be done within a matter of hours of donation, and significant wastage of tissue.

In 1983, 'UK Transplant', the NHS organ matching and distribution service, launched a national distribution service for ocular tissue. The great majority of corneas were supplied as whole eyes in moist chambers and were moved directly between donor and recipient hospitals. This service was enhanced in 1986 with the introduction of organ culture by the Bristol Eye Bank, which increased corneal storage time from 2-4 days (in M-K medium) to 28 days.

The Manchester Eye Bank opened two years later and became fully integrated into this service in 1989. Corneal transplantation, which for many surgeons had by necessity been an emergency out-of-hours operation, was now an elective procedure with corneas being supplied for named patients for scheduled grafts. Corneas were also always available for emergency grafts and the chance of obtaining tissue-matched grafts was greatly facilitated.

Since its inception, this service has supplied corneas for more than 30,000 transplants. The corneas are contributed from donors in hospitals throughout the UK, but the principal contributors are the other UK eye banks, at East Grinstead, Norwich and Moorfields, as well as Liverpool and Newcastle, which are supported under the National Eye Retrieval Scheme. All corneal grafts are now followed for five years through the Ocular Tissue Transplant Audit run by UK Transplant and the Royal College of Ophthalmologists. Studies in Bristol Eye Bank and clinical follow-up studies through UK Transplant have demonstrated the reliability and efficacy of organ-cultured corneal grafts.

This corneal transplant network relies on a high degree of cooperation between donor hospitals, the eye banks, UK Transplant and corneal transplant surgeons. The proliferation of small eye banks has been avoided and patients throughout the NHS have proper and fair access to ocular tissue whenever it is needed for their treatment.

THE EUROPEAN EYE BANK ASSOCIATION

Andrew B Tullo, MD, FRCOphth, Manchester Royal Eye Hospital, UK

The European Eye Bank Association (EEBA) first met in 1988 when a handful of people got together in Denmark. Since then there have been annual meetings in many different countries and each year a Directory is published giving activity levels and techniques used by over 70 banks in over 20 countries. The organization can now claim to speak with some authority on eye banking in Europe at a time when governments require higher standards and tighter regulation. The EEBA is a scientific group which can inform member banks on how to respond to these requirements.

MICROBIOLOGICAL AND MEDICAL THERAPEUTIC INFLUENCES

John Dart, MA, DM, FRCS, FRCOphth, Moorfields Eye Hospital, UK

Penetrating keratoplasty has remained a remarkably stable technique since the introduction of eye banking, nylon sutures and topical steroid therapy over 30 years ago. It is possible that the technique will become largely obsolete, giving way to anterior and posterior lamellar keratoplasty for many indications, except for situations in which there is a therapeutic role or full thickness corneal pathology.

So what has changed over the last 2 or 3 decades and what may change in future? The therapeutic indications have been reduced, in specialist centres, by better techniques for managing the situations for which it has been needed in the past: severe infection and corneal melting disorders. However the following techniques have helped manage these situations: systemic immunosuppression when topical therapy is inadequate to control the inflammatory response, glueing techniques to maintain the anterior chamber after perforations and permit control of the precipitating problem before surgery, viscodelamination of adherent iris, lens and cornea, at the time of surgery, and the use of tissue plasminogen activator at the end of the procedure or within 10 days of surgery, to degrade fibrin and potentially reduce the prevalence of iris/lens/cornea synechiae in the post-operative period. The development of the quinolone antibiotics both systemically and topically has lead to simpler management of acute infections with less toxicity than with the aminoglycoside and cephalosporin combination therapy. Intravitreal antibiotic prophylaxis and treatment is now a matter of course where indicated rather than an occasional technique.

In the post-operative period the availability of non-preserved topical therapy, modern therapeutic contact lenses with good oxygen permeability and serum drops for persistent epithelial defect have been helpful in high risk cases. The risks of recurrent disease after graft surgery for Herpes stromal keratitis have been reduced by the use of effective oral antiviral prophylaxis.

The downside of high risk therapeutic keratoplasty has been to lead to the new infectious process of infectious crystalline keratopathy. Creutzfeld-Jacob disease is potentially transmissible by keratoplasty and this has become a major influence on donor selection and graft instrumentation in the UK.

PENETRATING KERATOPLASTY INDICATIONS AT EAST GRINSTEAD OVER 10 YEAR PERIOD 1990-1999

Nada Al-Yousuf, MD, FRCS(Ed), Salmaniya Medical Complex, Kingdom of Bahrain

Background/aims

To determine the indications for penetrating keratoplasty (PK) in a specialist referral centre for over a 10 year period, and to compare the current series with a previous study performed in the same institution over a 20 year period.

Methods

Retrospectively, records of all patients who underwent PK at the Corneoplastic Unit and Eye Bank, East Grinstead, a tertiary referral centre, between 1990 and 1999 were reviewed. Of the 1096 procedures performed in this period, 784 records were available for evaluation (72%).

Results

Regrafting was the most common indication, accounting for 41% of all cases. Keratoconus was the second most common indication (15%), followed by Fuch's endothelial dystrophy (9%), pseudophakic bullous keratopathy, (8%), and viral keratitis (6%). Other corneal dystrophies, aphakic bullous keratopathy (ABK), injuries, interstitial keratitis (IK) and ulcerative keratitis accounted for most of the remaining cases.

Viral keratitis, as an indication for PK, showed a statistically significant decreasing trend using regression analysis ($p<0.005$). Among the regraft subgroup, Herpes infection accounted for the majority of cases (n=68, 21%) followed by corneal dystrophies (n=49, 15%), corneal edema (n=47, 14.6%), injuries (n=44, 13.7%), and keratoconus (n=41, 13%). The most common cause for graft failure in regraft subgroup was endothelial failure (n=134, 41.7%) followed by endothelial rejection (n=53, 16.5%). Primary failure accounted for 2.1% of all cause of graft failure in regrafts. All cases of primary failure occurred between 1990 and 1994.

Comparing our series with that previously reported from our institution between 1971 and 1990, regrafting was the commonest indication and identical at 41% in both series. Keratoconus was almost similar in proportion in both series. Fuchs dystrophy and PBK were significantly higher in the current series as compared with the previous. ($p<0.005$). Herpes infection, ABK, and IK were significantly higher in the previous series. ($p<0.005$).

Conclusion

Regrafting remains the most common indication followed by keratoconus. Grafting for Herpes Simplex has decreased significantly which may be as a result of improved therapeutic measures available and adopting a conservative approach. No cases of primary failure were noted after 1994 which suggests an improvement in eye banking methods.

POST-OPERATIVE COMPLICATIONS FOLLOWING PENETRATING KERATOPLASTY

David D Verdier, MD,
Michigan State University College of Human Medicine, USA

An overview of post-operative complications following Penetrating Keratoplasty will highlight important and sometimes overlooked complications. Topics will include recognition of subepithelial infiltrates as a form of rejection; prompt removal of broken or eroding sutures; aggressive use of punctal occlusion for surface healing problems; and discussion of traumatic ruptured globe in PK eyes.

DIAGNOSIS AND STAGING OF LIMBAL STEM CELL DEFICIENCY

Gary S Schwartz, MD,
University of Minnesota, USA

1. A stable ocular surface is dependent upon:
   a. Healthy conjunctiva
   b. Healthy cornea
      i. Endothelium
      ii. Epithelial limbal stem cells
   c. Structurally normal adnexa
2. Limbal stem cell deficiency
   a. Abnormal cells
      i. Aniridia
      ii. Corneal intraepithelial neoplasia
   b. Decreased number of cells
      i. Trauma
         1. Iatrogenic
         2. Thermal
         3. Alkali/acid
         4. Contact Lens
      ii. Inflammation
         1. Stevens-Johnson Syndrome
         2. Ocular cicatricial pemphigoid
         3. Atopic disease
         4. Acid/alkali injury
3. Staging System
   a. Amount of limbal stem cell lost
      i. Stage I: Less than 50% loss
      ii. Stage II: Greater than 50% loss
   b. Condition of conjunctiva
      i. Grade a: normal
         1. Aniridia
         2. Iatrogenic limbal stem cell deficiency
      ii. Grade b: abnormal but quiet
         1. Old alkali injury
      iii. Grace c: inflamed
         1. Recent alkali injury
         2. Stevens-Johnson Syndrome

SELECTION OF THE APPROPRIATE STEM CELL TRANSPLANT PROCEDURE

Edward J Holland, MD, University of Cincinnati, USA

The management of severe ocular surface disease has changed drastically over the last quarter century. Previously, patients with severe ocular surface disease had a very poor prognosis. The available techniques for visual rehabilitation included keratoplasty, tarsorraphathy, or preserved artificial tears. The outcomes of keratoplasty in this setting was uniformly poor due to the recurrence of ocular surface failure in the donor cornea.

The current surgical approach to manage severe ocular surface disease is epithelial transplantation. These procedures aim at replacing abnormal conjunctiva and/or limbal stem cells. The procedures vary based on the source of donor tissue whether it is self, cadaver, or living relative. The procedures also vary based on the tissues transplanted. Sources include conjunctiva, limbus, or cornea.

A variety of procedures have been described in the literature. Many of these procedures vary slightly however there are five basic operations available. These procedures include conjunctival autograft, conjunctival limbal autograft, living related conjunctival allograft, keratolimbal allograft, and amniotic membrane transplantation.

The technique of ocular surface transplantation has been built on the scientific findings of the anatomy of the ocular surface. Significant progress has been made over the last 2 decades improving the prognosis for these patients. However severe challenges still face us. These include improving the success rate of ocular surface transplantation which varies from fifty to seventy percent, reducing the risk of rejection which is the major cause of stem cell failure, developing safer immunosuppression protocols for the patients and finally, further development of ex-vivo expansion techniques.

CLINICAL APPLICATION AND SURVIVAL OF EX-VIVO EXPANDED LIMBAL EPITHELIAL ALLOGRAFTS

S Elizabeth James[1], Justin Sharpe[1], Caryn Brown[1], Keith Wood[1], Robin Martin[1], Osama Giledi[2], James O'Reilly[2] and Sheraz Daya[2,3], Blond McIndoe Research Centre[1], Corneo-Plastic Unit[2] and Eye Bank[3], Queen Victoria Hospital, East Grinstead, Sussex, UK

Purpose

Patients with persistent limbal deficiencies are unable to maintain a stable corneal surface and suffer severe visual difficulties. Sheets of cultured allogeneic corneal epithelium, prepared from limbal tissue, may help to repair these defects.

Methods

Biopsies of limbal tissue, 1-2mm^2, removed from cadaveric eyes, or a living relative (1 patient), were trypsinized and cultured to produce sheets of corneal epithelium which were applied to debrided eyes and covered with amniotic membrane. Samples of all tissues used on each patient's eye were collected and subjected to PCR Short Tandem Repeat (STR) DNA fingerprinting at 3 unlinked autosomal loci to monitor the fate of the cultured cells.

Results

Ten patients were studied. Each patient received cultured limbal allografts and their clinical recovery was followed over 3 – 3$^1/_2$ years (1st cohort), 1$^1/_2$ - 2 years (2nd cohort) and 4 - 9 months (3rd cohort).

- All eyes (all cohorts) re-epithelialized
- limbal barrier to conjunctival invasion restored (first 2 cohorts)
- Decreased vascularization in all cases
- Decreased inflammation in all cases
- 2 of 3 surfaces stable at 1 year (1st cohort)
- 2 of 3 surfaces stable at 1 year (2nd cohort)
- No rejection (early days for 3rd cohort)
- Improved comfort in all cases

First four patients have received subsequent corneal grafts to restore vision. In 3 of 4 cases, immunohistochemistry of the removed corneal button revealed a well-developed corneal epithelium. PCR STR genotyping of the removed tissue showed that the corneal surfaces no longer contained cells from the cultured sheets, but cells of the patients' own genotype. DNA isolated from surface impressions taken from other grafted patients at or beyond 4 months post graft, confirmed this finding but did show the presence of donor cells 8 – 10 weeks post graft.

Conclusions:

Cultured corneal epithelial allografts were able to contribute to the repair of corneal surfaces previously demonstrating prolonged and complete limbal deficiency. These results suggest that the cultured donor cells did not persist on the repaired corneal surface but may have contributed to the restoration of the patients' own limbal function.

THE AMNIOTIC MEMBRANE IN OPHTHALMOLOGY

Harminder S Dua, MBBS, DO, DO(Lond), MS, MNAMS, FRCS, FRCOphth, MD, PhD, University of Nottingham, UK

The amniotic membrane is now being used extensively in ophthalmic practice. The exact mechanism of action is not definitely known. Some of its beneficial effects are attributed to the numerous 'factors' that it contains, however, it is not yet clear whether these molecules survive the processing, preservation and storage techniques employed. The membrane is believed to inhibit scarring, inflammation and angiogenesis; has anti microbial effects and provides a substrate for epithelial cell growth and attachment both in vivo and in vitro for later transplantation on to the ocular surface.

Ophthalmic indications include ocular surface reconstruction in stem cell deficiency; persistent epithelial defects; conjunctival reconstruction, and bullous keratopathy. Its use is also recommended in glaucoma, oculoplastic and refractive surgery. In these indications it can be used as a patch, wherein it is applied as a 'biological bandage'; as a graft when it is expected to become covered by host epithelium and become incorporated into the host tissues; in multiple layers when it helps to build tissue; with its epithelial side up, which favours re-epithelialization or with its epithelial side down, which facilitates trapping of inflammatory cells and reduces inflammation. Two membranes may be used simultaneously one as a patch and one as a graft. Side-effects or complications associated with the membrane occur rarely but the risk of transmission of microbial infections such as HIV and hepatitis B and C are serious potential adverse effects.

The amniotic membrane holds a lot of promise. However, whilst it has been shown to be a useful and viable alternative for some conditions it is currently being used far in excess of its true useful potential. In many clinical situations it offers an alternative to existing management options without any distinct advantage over the others. Further studies will undoubtedly reveal the true potential of the membrane and its mechanism(s) of action.

AETIOLOGY OF LIMBAL STEM CELL TRANSPLANTATION FAILURE

Gary S Schwartz, MD, University of Minnesota, USA

1. Despite recent advancements, a significant percentage of limbal stem cell transplantations will go on to fail.
2. Limbal stem cell grafts fail more often than penetrating keratoplasty grafts.
   a. Underlying disease is usually more severe
   b. Transplanted cells represent a renewable cell line
   c. Cells are transplanted to the limbus rather than the central cornea.
   d. Early failure
3. Acute immunologic rejection
   a. Adnexal abnormalities
   b. Inflammation
   c. Severe acqueous and mucin deficiency
4. Late failure
   a. Sectoral conjuctivalisation
   b. Stem cell exhaustion
   c. Late immunologic rejection
5. Strategies to improve outcomes
   a. Pre-operative
      i. Address lid abnormalities
      ii. Maximise tear function
      iii. Suppress inflammation
   b. Post-operative
      i. Maximise immunosuppression topically and systemically
      ii. Perform frequent post-operative follow-up exams
      iii. Aggressively manage findings in early failure

POST-OPERATIVE MANAGEMENT FOLLOWING STEM CELL TRANSPLANTATION

By Edward J Holland, MD, University of Cincinnati, USA

Patients with bilateral limbal stem cell deficiency who are not candidates for autologous transplantation generally require allograft tissue to restore the stem cell population. Compared to conventional penetrating keratoplasty, limbal allografts are at significantly higher risk for rejection. This increased susceptibility to rejection is primary because of the vascularity of the limbal area, which allows greater access for the immune system. It is also due to the greater antigenicity of the limbal tissue, which contains a significant number of Langerhans' cells.

Previous studies have demonstrated the importance of immunosuppression and maintaining graft survival following a limbal stem cell transplantation. Our data demonstrates that achieving adequate immunosuppression after keratolimbal allograft requires oral immunosuppression and topical therapy alone is insufficient for long term graft survival.

The oral immunosuppression protocols that we have used include corticosteroid, azathioprine, (Imuran), cyclosporin A (neoral). More recently we have adopted a new protocol of corticosteroid, mycophenolate (cellcept), and tacrolimus (prograf). We found these regimens to be very well tolerated and significantly improve success rate of the stem cell transplant procedures.

The use of oral immunosuppressive agents requires careful monitoring and knowledge of the potential side-effects. The side-effects and adverse reactions due to these medications are the main potential cause of morbidity associated with limbal allograft transplantation.

KERATOPROSTHESIS - PROGRESS IN REDUCING COMPLICATIONS

Claes H Dohlman, MD, PHD, Harvard Medical School, USA

The following improvements will be discussed:

1. A KPro design that allows sufficient nutrition and hydration of surrounding corneal tissue.
2. Use of a type of soft contact lens post-operatively that ensures uniform hydration of the adjacent cornea.
3. Anti-inflammatory and anti-necrotic medications include not only topical corticosteroids but, at times, medroxyprogesterone, tetracycline and antibody to TNF-α.
4. Antimicrobial topical regimens that have completely prevented infections for the last two and a half years.
5. Use of glaucoma valve shunts – important in cicatrizing and autoimmune diseases.
6. A new technique of placing an additional tube between the shunt plate and lacrimal sac or nasal sinuses.
7. Techniques for vitreoretinal surgery with visualization through KPro.

THE OSTEO-ODONTO-KERATOPROSTHESIS

Christopher Liu, FRCOphth, Sussex Eye Hospital, Brighton, UK

Purpose

Early British followers of the Strampelli OOKP technique reported poor retention results. Falcinelli's modified technique has excellent long-term retention with 75% of patients seeing 6/12 or better. Our unit introduced the modified technique into Britain in 1996. We report our technique and medium term visual and retention results.

Methods

On going prospective study of all patients receiving OOKP surgery at our unit.

Results

25 patients had multi-staged OOKP surgery completed from March 1997 to July 2002. The mean age was 55.24 years (range 25 to 92 years). The mean follow-up since completion of surgery was 29.04 months (range 1 to 65) months. The pre-operative diagnoses were: Stevens Johnson syndrome (16), ocular cicatricial pemphigoid (3), alkali burn (3) trachoma (1). Ectodermal dysplasia (1) and radiation induced dry eye (1). Pre-operative visual acuities were PL (14), HM (9), CF (1) and 6/24 (1). Post-operative visual acuities were: 6/4 (1), 6/6 (3), 6/9 (4), 6/12 (2), 6/18 (1), 6/36 (2), 1/18 (1), CF (6), HM (3). One patient had her OOKP reversed due to previously undiagnosed severe macular scarring. One patient had his OOKP removed due to previously undiagnosed end stage glaucoma. One patient developed extrusion of the optical cylinder, two patients developed retinal detachment of two patients developed retro-prosthetic membrane function.

Conclusion

Our results confirm that OOKP is a valid technique for the corneal blind patient with a severe dry eye or keratinised ocular surface which is not amenable to conventional corneal transplantation. Such patients need not go through unsuccessful penetrating keratoplasty with or without stem cell and or amniotic membrane transplantation. Accurate pre-operative diagnosis pre-existing optic nerve or retinal problems will improve the visual outcome.

THE CHIRILA KERATOPROSTHESIS (ALPHACOR): BUILDING AN EVIDENCE BASE

Celia R Hicks, BA, MB Bchir, MA, FRCOphth,
Lions Eye Institute & Argus Biomedical, Perth, Australia

Clinical investigation of the Chirila keratoprosthesis, now known as AlphaCor, began in 1998. To date, over 40 devices have been implanted in patients deemed unlikely to benefit from a donor corneal graft. The device, surgical technique and outcomes to date are briefly described. The significance of the outcomes is discussed in relation to outcomes of high risk corneal grafts. The importance of developing an evidence-based approach to patient selection for AlphaCor surgery is discussed and a simple model for comparative outcome analysis is presented.

Acknowledgements:

The clinical investigation is supported by the National Health and Medical Research Council, Australia. As an employee of the Lions Eye Institute, Celia Hicks has a minor financial interest in the company commercializing the AlphaCor, Argus Biomedical Pty Ltd.

CURRENT ISSUES IN PHOTOTHERAPEUTIC KERATECTOMY (PTK)

Michaël Assouline, MD, PhD, Fondation Ophtalmologique A De Rothschild, Paris, France

Background

PTK uses the excimer laser ablation of the cornea to improve

- Surface regularity of the epithelium and the tear film
- Transparency of the anterior stroma
- Wound healing and adhesion of the epithelium

Patients and methods

An overview of current indications based on a retrospective study of 342 cases from 1992 to 2002. Representative case reports and outcome from a prospective series of 135 cases.

Results

Best corrected visual acuity was stable in 39.5% of patients, and improved with a gain of 2, 3 and 4+ lines in 15 (11%), 20 (14%) and 37 (26%) eyes respectively. Spherical equivalent shifted from +0.25±4.75 pre-operatively to +2.17±2.51 at one month and +1.20±2.03 at the last visit. Corneal surface regularity improved continuously over one year (Surface regularity index 2.82±2.22 to 1.25±2.63 at one month and 1.15±2.63 at the last visit).

Discussion

Surgical techniques (masking fluids, ablation patterns and profiles, prevention of hyperopic shift and irregular astigmatism) mostly depends on specific indications:

- Defective epithelial basal lamina (Cogan dystrophy, recurrent errosion)
- Defective Bowman's layer
  - with overlying fibrous metaplasia (Salzman degeneration, keratoconus, pterygium)
  - with exogenous deposits (Band keratopathy, amyloid deposits)
  - with inflammatory granuloma (EKC)with dystrophic structural changes (Reis-Bucklers)
- Endogenous dystrophic deposits in the anterior stroma or on corneal grafts (Granular dystrophy, macular dystrophy)

New indications are being investigated, including

- Bullous keratopathy
- Thygeson keratitis
- Epithelial invasion or flap folds after Lasik

Contra-indications and alternatives to PTK must be emphasised when considering PTK.

THURSDAY, NOVEMBER 14TH

DAY 1

8.30 - 9.30	Registration	
9.30 - 9.35	Welcome	Sheraz Daya

AM 1 — EYE BANKING — Moderators: Andrew Tullo & Mark Mannis

Sponsored by Alcon Laboratories (UK) Ltd

9.35- 9.45	The East Grinstead Eye Bank	Sheraz Daya
9.45 - 9.55	The Corneal Transplant Network UK	John Armitage
9.55 - 10.05	The European Eye Bank Association	Andrew Tullo
10.05 - 10.15	The Eye Bank Association of America	Pat Aiken O'Neill
10.15 - 10.30	DISCUSSION	
10.30 - 11.00	COFFEE BREAK	

AM 2 — PENETRATING KERATOPLASTY — Moderators: John Dart & David Verdier

Trends - Past and Future

11.00 - 11.20	Microbiological and Medical Therapeutic Influences	John Dart
11.20 - 11.40	Keratoplasty - History's Experiments and their Legacy	Mark Mannis
11.40 - 11.50	Penetrating Keratoplasty - Indications and Outcomes over Ten Years at East Grinstead	Nada Al-Yousuf
11.50 - 12.05	Post-operative Complications Following Penetrating Keratoplasty	David Verdier
12.05 - 12.15	Gene-based Approaches in Corneal Transplantation	Frank Larkin
12.15 - 12.25	DISCUSSION	
12.25 - 1.45	LUNCH BREAK	

PM — STEM CELL RESTORATION / KPRO — Moderators: Ed Holland & Harminder Dua

1.45 - 2.00	Diagnosis and Staging of Limbal Stem Cell Deficiency	Gary Schwartz
2.00 - 2.30	Selection of the Appropriate Stem Cell Transplant Procedure	Edward J Holland
2.30 - 2.40	Clinical Application and Survival of Ex-vivo Expanded Limbal Epithelial Allografts	Liz James
2.40 - 2.55	The Amniotic Membrane in Ophthalmology	Harminder Dua
2.55 - 3.05	DISCUSSION	
3.05 - 3.40	TEA BREAK	
3.40 - 3.50	Aetiology of Limbal Stem Cell Transplantation Failure	Gary S Schwartz
3.50 - 4.00	Post-operative Management Following Stem Cell Transplantation	Edward J Holland
4.00 - 4.10	Keratoplasty After Stem Cell Transplantation	Mark J Mannis
4.10 - 4.20	DISCUSSION	
4.20 - 4.35	Keratoprosthesis - Progress in Reducing Complications	Claes Dohlmann
4.35 - 4.50	The Osteo-odonto-keratoprosthesis	Christopher Liu
4.50 - 5.05	The Chirila Keratoprosthesis (AlphaCor): Building an Evidence Base	Celia Hicks
5.05 - 5.20	DISCUSSION	
7.30 - 8.00	PRE-DINNER DRINKS in the Desoutter Suite Foyer	Sponsored by Carl Zeiss Meditec Ltd
8.00	DINNER - Black Tie - Guest Speakers	David Paton & Chris Rudge

FRIDAY, NOVEMBER 15TH

DAY 2

AM	ADVANCED KERATOPLASTY TECHNIQUES *Sponsored by Advanced Medical Optics UK Limited*	Moderators: Mark Terry & Chad Rostron
9.00 - 9.10	Current Issues in Phototherapeutic Keratectomy (PTK)	Michaël Assouline
9.10 - 9.20	Lamellar Keratoplasty with Lyophilised Tissue - The St George's Experience	Chad Rostron
9.20 - 9.30	Deep Lamellar Keratoplasty - Outcomes Using a New Technique	James O'Reilly
9.30 - 9.40	Deep Lamellar Keratoplasty - A New and Innovative Surgical Technique	YY Choong
9.40 - 9.50	Tectonic Epikeratoplasty	Zbigniew Zagórski
9.50 - 10.10	DISCUSSION	
10.10 - 10.40	COFFEE BREAK	
10.40 - 10.55	Homoplastic Automated Lamellar Keratoplasty for the Treatment of Anterior Stromal Opacities	Sheraz Daya
10.55 - 11.10	Replacing the Endothelium Without Surface Corneal Incisions or Sutures - Deep Lamellar Endothelial Keratoplasty	Mark Terry
11.10 - 11.20	DISCUSSION	

	Paediatric Cornea	Moderators: Michael O'Keeffe & Sheraz Daya
11.20 - 11.35	Paediatric Keratoplasty - G.O.S.H!	Ken Nischal
11.35 - 11.50	Paediatric Keratoplasty - Dublin and East Grinstead	Michael O'Keeffe
11.50 - 12.05	Paediatric Refractive Surgery - The Next Frontier?	Deepinder Dhaliwal
12.05 - 12.20	DISCUSSION	
12.20 - 1.30	LUNCH BREAK	

PM	REFRACTIVE SURGERY *Sponsored by Bausch & Lomb UK Limited*	Moderators: Stephen Lane & Julian Stevens
	CORNEAL REFRACTIVE SURGERY	
1.30 - 1.40	Orbscan guided Wedge Resection for Residual Keratoconus	Luca Ilari
1.40 - 1.50	Laser In-situ Keratomileusis (LASIK) for the Treatment of Post-penetrating Keratoplasty Ametropia.	Marcela Espinosa
1.50 - 2.00	LASIK on PK	Stephen Lane
2.00 - 2.10	Managing Irregular Astigmatism, A Comparison of Two Lasers	Otto Wolter
2.10 - 2.20	LASEK? Preferable Choice for Low Myopia	Patrick Condon
2.20 - 2.30	Wavefront Guided Ablations - The Potential	Julian Stevens
2.30 - 2.40	Ocular Aberrations Following Standard LASIK	Jesús Merayo
2.40 - 2.50	Conductive Keratoplasty	Michael Belin
2.50 - 3.00	Permavision - A New Corneal Inlay	Sheraz Daya
3.00 - 3.10	Femtosecond Laser	Lou Probst
3.10 - 3.30	DISCUSSION	
3.30 - 4.00	TEA BREAK	
	INTRAOCULAR REFRACTIVE SURGERY	
4.00 - 4.10	Phakic Intraocular Lenses	Stephen Lane
4.10 - 4.20	Bioptics - Expanding Refractive Surgery Options	Erik Mertens
4.20 - 4.30	Presbyopia Surgery - Corneal or lenticular	Charles Claoué
4.30 - 4.40	DISCUSSION	
4.45	Closure of Meeting	Sheraz Daya

LAMELLAR KERATOPLASTY WITH LYOPHILISED TISSUE – THE ST GEORGE'S EXPERIENCE

Mr Chad K Rostron, MBBS, DO, FRCS, FRCOphth,
Moorfields Eye Department at St George's Hospital, London, UK

A retrospective analysis of all types of corneal grafts (n=324) performed over the past ten years was carried out. Around 35% of all keratoplasty procedures during this period were deep lamellar keratoplasty with freeze-dried (lyophilised) tissue (n=114). Indications for deep lamellar keratoplasty were: keratoconus 62%, corneal scarring 17%, herpes simplex 8%, lattice dystrophy 4%, various 9%.

There is good experimental evidence in animal models that when a lyophilised cornea is transplanted, it does not stimulate a rejection response, and does not sensitize the recipient to any donor antigens. Thus, should a lyophilised graft fail, and the patient requires a penetrating keratoplasty as the re-graft, their eye has not been pre-sensitized to any donor antigens. In clinical practice however, such a scenario is a fairly rare occurrence, and our penetrating re-graft rate on previous lyophilised lamellar grafts was 2%. Overall, during the study period, graft survival of lyophilised lamellar grafts was 94%, with 4% being re-grafted with a repeat lamellar procedure.

One concern that has been raised over the use of deep lamellar keratoplasty is the need to convert to penetrating keratoplasty if there is corneal perforation. However, if one is to concede to the possibility of conversion to penetrating keratoplasty, then the procedure is disadvantaged both by the need to have 'fresh' tissue available, as well as prejudicing the opportunity to carry out large grafts with their associated reduction of surgically induced astigmatism.

Our research has been directed to evolve a simple and reliable technique for lamellar keratoplasty that is not dependent on any special instrumentation, and that can be carried out on all cases where pre-operative recipient endothelial function is adequate.

When there is intra-operative perforation of the recipient bed, intra-operative or post-operative application of Tisseel fibrinogen adhesive (Immuno Ag., Vienna) can be used to seal the perforations, allowing the routine use of lyophilised tissue. The rate of elective conversion to penetrating keratoplasty at the time of lamellar surgery with this technique was 0.9%. This is on a par with the rate of primary graft failure in penetrating keratoplasty, suggesting that the need for the backup of 'fresh' tissue availability in deep lamellar keratoplasty is not a necessity.

DEEP LAMELLAR KERATOPLASTY - OUTCOMES USING A NEW TECHNIQUE

James O' Reilly, A Kerr, O Giledi, Luca Ilari, Sheraz Daya,
Queen Victoria Hospital, East Grinstead, UK

Institution
The Corneoplastic Unit, Queen Victoria Hospital NHS Trust, East Grinstead, West Sussex, United Kingdom.

Purpose
A new technique for Deep Lamellar Keratoplasty (DLK) is described. Outcome data of 38 eyes is presented.

Methods
Outcome data of patients who underwent DLK between January 2000 and February 2002 was reviewed.
A modified version of Melles technique was used in all cases; involving partial thickness trephination, anterior chamber air injection and deep dissection with a blunt spatula down to Descemet's membrane. The indication for grafting was visual in 27 eyes (Group 1; 15 keratoconus, 9 HSK, 3 other corneal opacification). Four grafts were tectonic (Group 2). Seven eyes (Group 3) had Ocular Surface Disease (OSD).

Results
Mean follow up was 15.7 months. Of the 27 eyes in group 1, a double anterior chamber formed in 8 eyes and resolved spontaneously in 7 eyes. One endophthalmitis developed post-operatively. Epithelial rejection occurred in 2 eyes.

Group 1 median BCVA was 6/18 (UCVA 6/48) at final follow up. Forty percent achieved 6/12 or better. Median BCVA improved to 6/9 in those followed for more than one year (n = 15 eyes). Sixty percent of these eyes achieved 6/12 or more.
Mean astigmatic cyclinder was –3.75 (SD 2.47) at final follow up. Suture removal an had unpredictable effect on astigmatism. Three patients underwent successful LASIK for the correction of severe astigmatism.

Tectonic grafting was initially successful in all four cases. Two eyes achieved 6/36. All 4 grafts remained clear. Vision was decreased due to cataract.
In Group 3, two grafts remained clear. Five eyes developed persistent epithelial defects related to underlying stem cell deficiency. Microbial keratitis occurred in 3 eyes necessitating repeat DLK in one eye.

Discussion
DLK is a safe procedure with minimal risk of rejection. Visual outcomes are good and post-operative astigmatism can be treated with LASIK. It is useful where penetrating keratoplasty is high risk. Our technique is safe and repeatable.

DEEP LAMELLAR KERATOPLASTY - A NEW AND INNOVATIVE SURGICAL TECHNIQUE

Dr YY Choong, MBBS(Mal), FRCS(Ed), Mmed(S'pore), AM (Mal), Sri Kota Medical Centre, Malaysia

This presentation demonstrates an innovative technique of separating Descemet's membrane from the stromal with deep air injection eases the technical difficulty in performing deep lamellar keratoplasty. This procedure shortens the operating time, has all the reported advantages of lamellar keratoplasty and possibly without the risk of having donor-host interface scarring.

TECTONIC EPIKERATOPLASTY

Zbigniew Zagórski, MD, E Rakowska, MD, B Rymgayllo-Jankowska, MD,
Medical University of Lublin, Poland

Introduction
Several options exist in the treatment of corneal melting, perforations or Descemetocoele: contact lens application, tissue glue, conjunctival patch graft, amniotic membrane transplantation and keratoplasty 'a chaud'. Since 1994 we are using, with increasing frequency, a full thickness donor corneo-scleral patch graft as tectonic epikeratoplasty. This method was introduced several decades ago in Odessa by Filatov and Pouchkovskaya.

Material and Methods
Since 1994 till 2002 we have treated 16 eyes of 15 patients with Mooren ulcer (2), viral keratitis with corneal melting (4), corneal perforations in the course of sicca syndrome (4), ocular cicatricial pemphigoid (2) and Stevens-Johnson syndrome (2) and in 2 eyes with the melting of a failed corneal graft. Full thickness donor corneo-scleral grafts were obtained from the local eye bank. In majority they were unsuitable for penetrating keratoplasty because of the endothelial status. The donor material was stored in Optisol from 2 till 8 days at 4°C. Donor corneo-scleral buttons were sutured over the diseased cornea in 5 eyes directly and in 11 eyes after 360° peritomy. In 11 eyes amniotic membrane was applied under the tectonic graft. The graft remained in place from 4 weeks to 3 years. In 5 eyes it has gradually dissolved, in 6 was removed and in 5 left in situ. When indicated patients were treated with systemic immuno-suppression or antivirals.

Results: Corneal perforations closed in all cases. In 4 eyes penetrating keratoplasty was performed for optical reasons, in 6 cases surface problems were treated further with amniotic membrane and in 4 with limbal transplantation In 2 eyes the cornea perforated again after 3 months and was treated with amniotic membrane transplantation in one and with second tectonic epikeratoplasty in another eye.

Conclusions
In severe cases of corneal perforation and/or melting, where keratoplasty has poor prognosis and other methods are unsuccessful, tectonic epikeratoplasty is a good alternative of treatment. Full circle peritomy and suturing the conjunctiva to the periphery of transplant prolongs the graft survival.

HOMOPLASTIC AUTOMATED LAMELLAR KERATOPLASTY FOR THE TREATMENT OF ANTERIOR STROMAL OPACITIES

Sheraz M Daya, MD, Marcela M Espinosa. MD, Luca Ilari, MD,
Queen Victoria Hospital, East Grinstead, UK

Purpose

Homoplastic Automated Lamella Keratoplasty (HALK) is a lamellar technique to treat mid-anterior stromal opacities with the use of a microkeratome. This ongoing study aims at evaluating the efficacy and safety of this promising surgical procedure.

Methods

33 eyes (30 patients) have been treated since 1997. The main indications were anterior stromal opacities secondary to Reis-Buckler's dystrophy, anterior stromal dystrophy and post-refractive surgery haze. HALK was used as a tectonic procedure in a patient with an impending corneal perforation.

Results

The mean follow-up was 19 months (range from 1 to 60 months).

At the one year follow-up 83% of patients had an improvement in uncorrected and best corrected visual acuity (UCVA and BCVA). An improvement in BCVA was evident as early as one month following HALK, with 59% of patients able to read 6/12 or better. Flap related complications occurred in 2 patients while three eyes suffered an episode of rejection successfully treated with intensive topical steroids.

Conclusions

HALK succeeded in restoring corneal clarity in all cases. Visual recovery was found to be rapid. This is a valid alternative to penetrating keratoplasty and phototherapeutic keratectomy in the treatment of anterior corneal opacities.

REPLACING THE ENDOTHELIUM WITHOUT SURFACE CORNEAL INCISIONS OR SUTURES - DEEP LAMELLAR ENDOTHELIAL KERATOPLASTY

Mark A Terry, MD, Devers Eye Institute, Portland, Oregon, USA

Deep Lamellar Endothelial Keratoplasty (DLEK) is a surgical technique for the replacement of the corneal endothelium entirely through a limbal scleral tunnel incision. This technique obviates the need for any corneal incisions or sutures, and preserves the corneal surface from limbus to limbus. The inherent value of this technique is that it allows preservation of the normal corneal topography, faster and stronger wound healing, and the avoidance of suture related problems such as induced astigmatism, unpredictable corneal power, infection, ulceration, and suture-induced vascularisation leading to graft rejection. The current challenges of this technique are the technical difficulty of the procedure and the challenges in consistently obtaining an optically pure interface.

While the procedure is still in evolution, the current basic surgical steps are the following:

1. A 9mm scleral incision is made with a guarded diamond knife set at a depth of 0.35mm, parallel to the limbus and 1 to 2mm peripheral to it.
2. Healon is injected through a stab incision at 10:00 o'clock into the Anterior Chamber to maintain it and modulate IOP.
3. A mid to deep corneal pocket is formed from limbus to limbus using the Devers Dissectors (straight and curved).
4. Healon is released from the AC through the stab incision and the 8.0mm Terry Trephine is placed into the pocket, centered over the pupil and trephination of the posterior disc of the recipient is done until the AC is entered.
5. The posterior disc trephination is completed with intracorneal, low profile, highly curved 'Cindy' scissors and the disc is removed and measured for diameter and thickness.
6. The Healon is completely aspirated from the AC and the interface with a Simcoe needle and replaced with BSS.
7. The donor cornea-scleral tissue is placed in the Artificial Ant Chamber and the donor posterior button is prepared. An automated Microkeratome or a manual resection of the anterior donor stroma can be done.
8. The donor tissue is mounted on a punch block, and the same size, 8.0mm donor trephine is used to punch out the posterior donor disc.
9. The donor disc is placed, endothelial side down, onto an Ousley insertion spatula which is previously coated with Healon.
10. The anterior chamber of the recipient patient is filled with Air.
11. The donor disc on the Ousley spatula is placed into the pocket, into the Ant Chamber and then lifted anteriorly into the posterior stromal recipient bed. It is held in position for 3 or 4 seconds and then the spatula is gently slid on the layer of Healon out of the eye, leaving the disc in place.
12. Air is immediately injected in to the AC to secure the graft.
13. The donor disc position is gently adjusted for good coaptation of the edges and any air in the interface is removed with a Sinsky hook.
14. The wound is closed with five to seven 10-0 nylon sutures, the conjunctival peritomy is closed with sutures.
15. The air bubble in the AC is completely removed and a collagen shield soaked in Ancef and Decadron is placed on the eye.
16. The eye is patched over Tobradex ointment and the patch removed the next day.

Currently, DLEK is being investigated by the Endothelial Keratoplasty Group (EKG), which consists of about 25 US sites and 10 international sites. This prospective, multi-site study is being done under strict Institutional Review Board (IRB) approval, and should allow a controlled investigation of the full potential for this procedure as it evolves. This procedure should not be performed at this time without local IRB approval.

References

1. Terry MA, Ousley PJ. Endothelial replacement without surface corneal incisions or sutures: topography of the deep lamellar endothelial keratoplasty procedure. *Cornea* 2001; 20:14-18.
2. Terry MA, Ousley PJ. Deep lamellar endothelial keratoplasty in the first United States patients: Early Clinical Results. *Cornea* 2001;20:239-243.
3. Terry MA, Ousley PJ. Endothelial replacement without surface corneal incisions or sutures: First U.S. clinical series with the Deep Lamellar Endothelial Keratoplasty Procedure Ophthalmology 2002 (In Press).
4. Terry MA. Endothelial Replacement: The Limbal Pocket Approach, Ophthalmology Clinics of North America 2002 (In Press).
5. Terry MA and Ousley PJ. Corneal Endothelial Transplantation: Advances in the Surgical Management of Endothelial Dysfunction. Contemporary Ophthalmology 2002 (In Press).
6. Terry MA. Deep Lamellar Endothelial Keratoplasty (DLEK): Pursuing the Ideal Goals of Endothelial Replacement. Eye 2003 (In Press).
7. Terry MA, Ousley PJ. The New Triple Procedure: First World Wide Patients with DLEK combined with Phaco/IOL surgery. American Academy of Ophthalmology Video Library, Annual Meeting, October 2002.
8. Terry MA, Ousley PJ. Endothelial replacement without surface corneal incisions or sutures: Deep lamellar endothelial keratoplasty. American Academy of Ophthalmology: Teaching Videos for purchase. 'Best of Show' AAO 2000.
9. Terry MA. The Deep Lamellar Endothelial Keratoplasty Procedure. Video Journal of Ophthalmology: 4th Quarter Edition, Dec 2000.
10. Terry MA. The evolution of lamellar grafting techniques over 25 years. *Cornea* 2000;19:611-616.
11. Melles GR, Eggink FA, Lander F et al. A surgical technique for posterior lamellar keratoplasty, *Cornea* 1998;17:618-626.
12. Melles GR, Remeijer L, Geerards AJM, Beekhuis H. The future of lamellar keratoplasty. *Current Opinion in Ophthalmology* 1999;10:253-259.
13. Melles GR, Lander F, van Dooren BR et al. Preliminary clinical results of posterior lamellar keratoplasty through a sclerocorneal pocket incision. *Ophthalmology* 2000;107:1850-1856.
14. Melles GR, Lander F, Nieuwendaal C. Sutureless, posterior lamellar keratoplasty: a case report of a modified technique. *Cornea* 2002;21:325-327.
15. Melles GR, Lander F, Rietveld FJR. Transplantation of descemet's membrane carrying viable endothelium through a small scleral incision. *Cornea* 2002;21:415-418.

G.O.S.H.! PAEDIATRIC KERATOPLASTY

Ken Nischal, Institute for Child Health, UK

At Great Ormond Street Hospital for Children, there are two indications for pediatric keratoplasty: tectonic and therapeutic.

Methods

All children undergo pre-operative assessment including electrodiagnostics, ocular ultrasound and high frequency ultrasound evaluation. Only after counselling of parents with a liason sister is surgery offered. Techniques of penetrating keratoplasty for Peters' /Sclerocornea and for deep anterior lamellar keratoplasty are discussed.

Results

Since January 1999 until September 2002, 5 tectonic corneal grafts have been performed (Peters' anomaly spontaneous rupture x2, Descemetocoele x3) and 2 tectonic scleral patch grafts for scleral melts. 19 penetrating keratoplasties and 3 deep anterior lamellar keratoplasties.

All 3 deep anterior lamellar keratoplasties have been performed using high frequency ultrasound guidance and all three have been in children with mucopolysaccharidoses.

14 of the 19 PKP's have been in children with Peters' anomaly or sclerocornea (74%). 4 of 14 had kerato-lenticular adhesions and needed lensectomy. All 14 had iridocorneal adhesions. Glaucoma was only seen in 3 cases (all with Peters' anomaly).

Follow-up ranges from 3 years to 1 month. Graft survival with or without medical rescue runs at 13/19 ie 68% and 8/14 for Peters' anomaly/Sclerocornea (57%).

Discussion

Indications for tectonic and therapeutic keratoplasty are discussed as are the post-operative management strategies.

Conclusion

Careful surgery, meticulous post-operative follow-up and intensive pre-operative counselling ensures that children with corneal problems necessitating keratoplasty are given the best chance of success. The child's eye is unique and keratoplasty techniques must be adapted to take this into account.

PAEDIATRIC KERATOPLASTY - DUBLIN AND EAST GRINSTEAD

Michael O'Keeffe, National Children's Eye Unit, Dublin,
Sheraz Daya, Queen Victoria Hospital, East Grinstead, UK

The aim of the Paediatric Keratoplasty is to prevent amblyopia and allow normal development of vision. Keratoplasty has a significantly lower success rate in Children compared to Adults, with success rate even lower in infants with congenital corneal opacity. In this presentation we report our experience in patients with Peter's Anomaly, Sclero Cornea, Posterior Polymorphus Dystrophy, Congenital Hereditary Endotheliel Dystrophy. Although surgery carries increased risk of failure, careful patient selection, optical correction and management of post-operative care including amblyopia, may result in successful visual outcome.

PEDIATRIC REFRACTIVE SURGERY - THE NEXT FRONTIER?

Deepinder K Dhaliwal, MD, Chief of Refractive Surgery, University of Pittsburgh School of Medicine, USA

SUMMARY

Refractive surgery in the adult population has gained acceptance and popularity worldwide. The pediatric population has many special considerations and there seem to be some situations in which refractive surgery may be medically indicated. One such indication is anisometropic amblyopia in children who have failed conventional therapy. Results and complications of LASIK for anisomyopic amblyopia in the pediatric population will be reviewed. Specific modifications necessary in the LASIK procedure will be discussed in detail, including type of anesthesia, choice of microkeratome, and fixation technique.

ORBSCAN GUIDED WEDGE RESECTION FOR RESIDUAL KERATOCONUS

Luca Ilari, Osama Giledi, Sheraz M Daya,
Queen Victoria Hospital, East Grinstead, UK

Penetrating keratoplasty is a widely established and successful procedure for the surgical treatment of keratoconus. However, failure to excise the entire diseased corneal tissue may in time lead to progressive corneal ectasia with graft tilt and induced astigmatism from progression of the residual keratoconus. Traditional management in these cases has included astigmatic keratotomy with or without compression sutures and repeat penetrating keratoplasty. With advances in technology, including corneal topography by Orbscan II (Bausch & Lomb, Rochester, NY, USA) we have a better understanding of corneal shape including precise identification of ectasia and elevated areas contributing to astigmatism. We present six cases of progressive keratoconus in the host post-penetrating keratoplasty treated with a wide crescentic excision of the diseased tissue in the host cornea guided by Orbscan II data. Detailed surgical technique and results will be discussed.

LASER IN SITU KERATOMILEUSIS (LASIK) FOR THE TREATMENT OF POST-PENETRATING KERATOPLASTY AMETROPIA

Marcela M Espinosa, MD, Luca Ilari, MD, Wilbert Hoe, MBBS, FRCS, FRCOphth, Osama Giledi, FRCSEd, James O'Reilly, FRCOphth, Sheraz Daya, MD, FACS,
Centre for Sight and Corneoplastic Unit, Queen Victoria Hospital, East Grinstead, UK

Purpose
To evaluate the safety and efficacy of LASIK in the management of ametropia following penetrating keratoplasty (PK).

Methods
62 eyes (56 patients) have been treated since 1997 this institution. The majority (72.6%) had PK for keratoconus. Mean interval between graft and Lasik was 7.6 years. The mean pre-operative spherical equivalent was –3.04 ± 4.3 dioptres. Mean pre-operative astigmatism was 4.91D (SD: 2,41). In 10 eyes (10 patients) LASIK was combined with astigmatic keratotomy performed under the flap for the correction of high degrees of astigmatism. More latterly a bitoric ablation was used to treat high levels of astigmatism

Results
The median follow-up was 27 months ranging from 6 to 60 months The mean spherical equivalent decreased to –2.08 D (SD 2.39) at 2 years. Uncorrected visual acuity of 20/40 or better was achieved in 40%. 54% of patients obtained an improvement in best spectacle corrected visual acuity with 28% gaining 2 lines or more.

Conclusions
LASIK is a safe and effective procedure for the treatment of post-penetrating keratoplasty ametropia with rapid visual recovery and minimal patient discomfort.

THE CORRECTION OF REFRACTIVE ERRORS WITH LASIK FOLLOWING PENETRATING KERATOPLASTY

Stephen S Lane, MD, University of Minnesota, USA

There can be significant refractive unpredictability following penetrating keratoplasty (PK). Current options for correction include astigmatic keratotomy, regraft, lensectomy with toric IOL implantation and LASIK. Advantages and disadvantages exist for each. Advantages for LASIK include: expanded range of treatable refractive errors, predictability, potential for enhancement, and low risk of scarring. Concerns include: potential weakening of the wound, induction of graft rejection, and uncertain predictability.

33 eyes underwent LASIK following PK. 76% were keratoconus patients. Mean number of months from PK to LASIK was 62 months. Mean refractive error preLASIK was 6.2D and mean cylindrical refractive error was 6.0D. Mean % reduction in sphere following LASIK was 81% and mean reduction in cylinder following LASIK was 65%. Complications included 3 cases of diffuse lamellar keratitis (DLK), 1 buttonhole flap, and 1 slipped flap. There were no graft rejections. LASIK following PK is a safe and effective procedure for reducing refractive errors.

Managing Irregular Astigmatism: A Comparison of Two Excimer Lasers

Otto Wolter, MD, Aruba Laser Refractive Institute, Dutch Caribbean

Since irregular astigmatism of any cause induces great visual discomfort, it has been a great challenge in the laser refractive surgery to understand this situation and to resolve the visual problems in these unhappy patients. In our Institution it has been a major goal to resolve somehow these problems for the past six years. For this reason I decided to review the outcomes in the few Lasik patients that have been helped in our Center and have had a good follow-up rate and done with the Kerakor 117C Plano-scan excimer Laser and topographic 'Linked' ablations for irregular astigmatism versus the Lasik patients using the Cap planner method of Visx Star S2 and S3 excimer laser.

For both excimer lasers the Humphrey Zeis Atlas Topography has been used version 9.0 and 10.0 and elevation map.

A follow-up rate of 90% over 5 years for the Chiron Technolas excimer laser and of 90% over three years for the Visx excimer laser has been registered.

With both excimer laser systems there was a significant improvement of visual acuity as well as improvement of the quality of vision, however, there was some regression with both lasers in the cases of irregular astigmatism due to status post PKP and post RK.

We believe and hope that these techniques in combination with the wave-front technology let us understand, plan and achieve better outcomes and perhaps more "stability over the years" as what we have achieved with these earlier methods.

Graphic of results will be shown.

LASEK? PREFERABLE CHOICE FOR LOW MYOPIA

Patrick Condon, FRCS, FRCOphth, Waterford Eye Clinic, Ireland

412 and 509 eyes had LASEK and LASIK carried out respectively over the last 48 month period of which 202 of the LASIK eyes and all of the LASEK eyes under –6.00 myopia pre-operatively.

Predictability
Attempted versus achieved refraction at 3 months post-operatively showed 85% of LASEK and 74% of LASIK with + or - 0.5D with an average refraction of –0.1D and -0.3D for LASEK and LASIK respectively.

Efficacy
Whereas 95% of both groups had UCVA of 6/12 at 3 Mts, 65% of LASEK had 6/6 UCVA compared to 45% of LASIK.

Safety
Both groups ended up with 80% BCVA of 6/6 at 3 Mts and neither group lost 2 lines or more vision over time.

Complications
Apart from the 3 eyes which developed an infection with the contact lens in the first 3 days post-operatively, the only other complications in the LASEK group were the 5 eyes (1%) which because of being over or under corrected required an enhancement procedure in the form of a LASIK operation which were extremely successful.
In the LASIK group flap infection occurred in 2 eyes. Whereas the overall enhancement rate in this group was 10% this seemed to occur in the predominantly higher degrees of myopia, none being required in the lower ones. Other complications in the LASIK group were Microstriae in 7, Sands of Sahara in 7 and epithelial ingrowth in 2, with an overall microkeratome failure rate occurring in 14 eyes (2.7%) using the Alcon SKBM microkeratome.

Summary
Apart from the 6/6 UCVA rate of 65% at 3 Mts. In the LASEK group compared to 45% in the LASIK group which was probably related to flap induced aberrations, there was little difference in the results of both groups in treating low myopia. The relatively low incidence of MK failure in the LASIK group will obviously improve with better designed instruments by which stage LASIK will then be a safer procedure.

WAVEFRONT GUIDED ABLATIONS – THE POTENTIAL

Julian D Stevens, MRCP, FRCS, FRCOphth,
Moorfields Eye Hospital, London, UK

New methods of measurement of the optical properties of the human eye by wavefront scanning have led to a new understanding of the effects of the procedures we are performing to patients. This diagnostic capability has become integrated with the therapeutic capacity of the excimer laser and has led to wavefront-guided excimer laser ablation. At the present time wavefront treatment to the cornea has been performed as LASIK, LASEK and PRK and treatment has been as a primary wavefront guided treatment or as a therapeutic enhancement procedure after previous refractive surgery. This presentation will demonstrate the effects of wavefront-guided treatment for high spherical aberration and after previous irregular PRK, LASIK and radial keratotomy.

OCULAR ABERRATIONS FOLLOWING STANDARD LASIK

Jesús Merayo-Lloves, MD, IOBA, University of Valladolid, Spain

Purpose

To analyze total and corneal aberrations after standard LASIK for myopia and hyperopia.

Methods

Myopic and hyperopic subjects candidates for LASIK were measured for total and corneal aberrations before and after surgery. Total aberrations were performed with a ray tracing wave front sensor and corneal aberrations were obtained with a corneal topographer. All patients were operated by the same surgeon and with the same instruments (Hansatome microkeratome & 217-C LASIK excimer laser).

Results

Total and corneal aberrations increased after LASIK treatment twofold. The largest contributor was spherical aberration. In Myopic subjects the induced spherical aberration was positive but partially masked by the myopic crystalline lens that has negative spherical aberration. In hyperopic patients spherical aberration was negative and the tendency to increase aberrations was greater than in myopes. Corneal aberrations do not correspond to total, indicating the importance of biomechanical factors in the final refractive result.

Conclusion

Standard LASIK induces optical aberrations that can influence the quality of vision. New software for corneal sculpture should ideally manage reduction of (spherical) aberrations. Differences in total and corneal aberrations provides information about biomechanical changes after LASIK and also information of the differences among the lens of myopic and hyperopic eyes, that should be taken in account for intraocular lens design.

CONDUCTIVE KERATOPLASTY

Michael W Belin, MD, Robert L Schultze, MD,
Cornea Consultants of Albany, New York, USA

Conductive keratoplasty (CK) is a non-ablative, collagen shrinking procedure. As opposed to LTK which is laser based, CK is based on the delivery of radiofrequency energy through a fine conducting tip inserted into the peripheral corneal stroma. Because of its electrolytic properties, the cornea conducts radiofrequency energy. As the current flows through the tissue surrounding the tip, resistance to the current creates localized heat. Collagen lamellae in the area surrounding the tip shrink in a controlled fashion and form a column of denatured collagen.

The ViewPoint™ CK system for performing conductive keratoplasty consists of a portable console, a lid speculum that acts as the electrical return path, and a hand-piece that holds the 450 µm long and 90 µm wide metal tip (Keratoplast™ Tip). For hyperopia treatment, the surgeon inserts the tip into the stroma at defined spots in a ring pattern around the peripheral cornea according to the supplied nomogram. The number and location of spots determines the amount of refractive change, with an increasing number of spots and rings used for higher amounts of hyperopia.

Conductive keratoplasty and LTK differ in several respects. In LTK, heat is applied directly to the corneal surface, resulting in a thermal gradient in which the treatment is hotter at the surface and cooler in the deeper stroma. The resulting footprint of denatured collagen is conical, wider on the surface and tapering in the stroma. CK-treated tissue is exposed to the same temperature at the tip of the probe (deep in the stroma) as at the top of the probe (the corneal surface). Confocal microscopy and histology show a deep (approximately 80% of the corneal depth), cylindrical footprint. Histologic studies of the pig cornea show confirms that the footprint made by CK is cylindrical and extends deep into the stroma. Striae form between the treated spots, creating a band of tightening that increases the curvature of the central cornea. The deeper more consistent collagen shrinkage with CK is expected to produce a more stable effect.

CK appears to have advantages both in initial cost and flexible (off-label) treatment patterns. Since the tip can be placed anywhere in the cornea, CK may be useful for treating astigmatism after LASIK or cataract surgery, replacing incisional enhancement procedures, such as astigmatism keratectomy or limbal relaxing incisions. When used to correct astigmatism, the surgeon must customise the procedure and apply selected spots to steepen the necessary axis. Treatment can be performed at the slit-lamp in a standard examination room instead of a surgical suite.

PERMAVISION – A NEW CORNEAL INLAY

Sheraz M Daya, MD, Marcela Espinosa, MD,
Queen Victoria Hospital, East Grinstead, UK

The concept of a corneal inlay to correct refractive error is not new and a variety of materials have been tried with little success in the past. Inlays have the advantage of being reversible and adjustable and are ideal in refractive surgery.

Permavision (Anamed Inc. CA) is a new device made from Hydrogel and is currently under investigation. Presently the device is used for the treatment of hyperopia and limited trials of a myopic implant have begun. The technique of implantation and outcomes in 12 eyes over a period extending to 18 months will be described.

FEMTOSECOND LASER

Lou Probst, MD, TLC Vision inc., USA

The Intralase femtosecond laser offers to revolutionize flap creation in LASIK. The principles of this new technology and digitized videos of flap creation will be presented. Emphasis will be placed on the practical value of this new technology in a current refractive practice. Challenges of the current system will be reviewed including recent experience in the USA.

CURRENT STATUS OF PHAKIC REFRACTIVE LENSES IN THE US

Stephen S Lane, MD, University of Minnesota, USA

Phakic refractive lenses can be divided into 3 categories: those that are placed in the anterior chamber (AC), those that are placed in the posterior chamber (PC), and those attached to the iris. Each has its own unique advantages, disadvantages and insertion technique. Critical to the success of AC lenses is prevention of iris ovalization and angle structures, and maintenance of endothelial integrity. Critical to the success of PC lenses is prevention of cataract and atraumatic insertion. Lens designs, insertion techniques, and data from FDA clinical trials will be presented for lenses in each category.

BIOPTICS - EXPANDING REFRACTIVE SURGERY OPTIONS

Erik L Mertens, Antwerp Eye Centre, Belgium

Purpose

To evaluate the accuracy, reliability and safety of this combined surgical technique.

Methods

159 eyes patients underwent phakic IOL implantation followed by LASIK correction of the residual refractive error. Three to ten days after creation of a corneal flap an Artisan IOL was implanted under topical anesthesia. Minimally one month after implantation and after stabilization of the refraction LASIK was performed. Follow-up to five years was achieved.

Results

93% of eyes gained at least one line of BSCVA. Only one case needed enhancement.

Conclusions

The combination of Artisan lens implantation and LASIK for correction of high ametropia and astigmatism gives extremely good results in terms of optical quality and predictability for a higher surgical risk.

PRESBYOPIA SURGERY - CORNEAL OR LENTICULAR?

Mr Charles Claoué, MA (Cantab), MD, DO, FRCS, FRCOphth,
Whipps Cross University Hospital, London,
Medical Director at OptimEyes Laser Consultant, UK

Presbyopia remains the forgotten refractive error as shown by the fact that the commonest complication of 'successful' lens surgery is absolute presbyopia. It is also the commonest refractive error being universal from the age of 45 onwards.

Three anatomical sites have been suggested for surgical reversal of presbyopia: the sclera, the cornea and the crystalline lens. Scleral surgery has been incisional with or without insertion of implants, or laser. The evidence for efficacy and permanence has not been universally accepted with many reports suggesting at best a transient effect.

Corneal surgery appears more attractive to many refractive surgeons. The cornea is the current preferred site for myopia and astigmatism surgery as well as low hypermetropia. However, either the creation of corneal monovision or corneal multifocality has been promoted as corneal presbyopia surgery. Such surgery has limitations in terms of stereopsis and quality of vision.

PRELEX is the current name for a procedure described in 1997 by this author, in which the crystalline lens is replaced by a pseudoaccommodative IOL. This appears the most rational and predictable surgery in 2002 and will be discussed in detail.