Cornea Update

DALK & Endothelial Keratoplasty

Sheraz Daya
MD FACP FRCS(Ed) FRCOphth

CENTRE FOR SIGHT

DEEP ANTERIOR LAMELLAR KERATOPLASTY

CENTRE FOR SIGHT

Indications for Lamellar Keratoplasty

"WHENEVER THE ENDOTHELIUM IS NORMAL"

CENTRE FOR SIGHT

Anterior Lamellar Keratoplasty

- **Advantages**
  - Retains endothelium
  - Reduces risk of corneal blindness
- **Disadvantages** (previously)
  - Poor Vision
    - Interface opacification
    - Regular and Irregular Astigmatism
  - Technical skill
    - Perforation

CENTRE FOR SIGHT

DALK – Why ?

- "Primo No Nocere"
- SAFETY
- SURVIVAL – long term
- OTHER...

CENTRE FOR SIGHT

PK can be HAZARDOUS !!!

CENTRE FOR SIGHT

PK – Hazards...

- Expulsive Choroidal Haemorrhage 0.56*-1%
- Rejection & Failure
- Reduced survival of Regrafts
- Glaucoma 19- 30%
- Cataract
- Endophthalmitis

CENTRE FOR SIGHT

PK – long term...

EXTENDED REPORT

Penetrating keratoplasty: outcomes from a corneal unit compared to national data

P Beckingsale, I Mavrikakis, N Al-Yousuf, E Mavrikakis, S M Daya

Table 1 Three year graft survival rates for national outcome data (UKT) and Queen Victoria Hospital (QVH)

Diagnosis	UKT 3 year graft survival rates (%)	QVH 3 year graft survival rates (%)	p Value
Keratoconus	93	98	0.019
PBK	83	90	0.00003
Fuchs' dystrophy	87	90	0.67
Viral keratitis	77	86	0.002
Regrafts	57	67	0.002
Total	79	81	0.15

CENTRE FOR SIGHT

DALK - Techniques

- Injection of air into the stroma – big bubble
- Injection of water / viscoelastics
- Stromal Air Injection
- Ferrara Ring Dissection
- Optical recognition - Melles
- Modification of Melles's technique

CENTRE FOR SIGHT

'DALK and Endothelial Keratoplasty'

(slides 1-16)

Sheraz Daya
MD FACP FRCS(Ed) FRCOphth

DALK – How ?

- Descemet's
  - Big Bubble – *Anwar*
  - Viscodissection
- Pre-Descemet's
  - Optical Recognition – *Melles*
- Femtosecond Assisted

CENTRE FOR SIGHT

Deep Anterior Lamellar Keratoplasty

Sheraz Daya MD

www.centreforsight.com

CENTRE FOR SIGHT

Do Lamellars Reject ?

Epithelial Rejection

Sub-epithelial Rejection

CENTRE FOR SIGHT

DALK vs PK for Keratoconus

Authors	Number of eyes	BCVA ≥ 20/40	BCVA ≥ 20/30
Deep Anterior Lamellar Keratoplasty for keratoconus			
This study	33	34.2%	50%
coombes et al [1]	37	55%	54%
Watson et al [2]	25	87.5%	N/A
Anwar et al [3]	191	69%	27%
Funnel et al [4]	20	35%	N/A
Penetrating Keratoplasty for keratoconus			
Buzard et al [5]	194	89%	36%
Lin et al [6]	30	67%	N/A
Watson et al [2]	22	68%	N/A
Funnel et al [4]	20	65%	N/A

CENTRE FOR SIGHT

Indications for Lamellar Keratoplasty

- "WHENEVER THE ENDOTHELIUM IS NORMAL"

CENTRE FOR SIGHT

POSTERIOR LAMELLAR KERATOPLASTY

CENTRE FOR SIGHT

POSTERIOR LAMELLAR KERATOPLASTY

- ENDOTHELIAL FAILURE
- Cornea Oedema
  - Fuchs Endothelial Dystrophy
  - Pseudophakic Bullous Keratopathy
  - ICE Syndrome – endothelial failure

CENTRE FOR SIGHT

FUCHS DYSTROPHY

CENTRE FOR SIGHT

Pseudophakic Bullous Keratopathy



Endothelial Failure

- Traditional approach = Penetrating keratoplasty
- Problems
  - Sutures & suture related problems
  - Rehabilitation – 1 year approx
  - Frequent follow up
  - Open-sky – hazardous
  - Astigmatism – regular & irregular

Endothelial Failure

- Why not just replace the endothelial layer ?
  - Anterior corneal stroma is normal
  - Smaller incision outside cornea
  - Less astigmatism
  - More rapid rehabilitation
- CHALLENGE:
  - Keep the endothelial cells in place
  - Graft survival



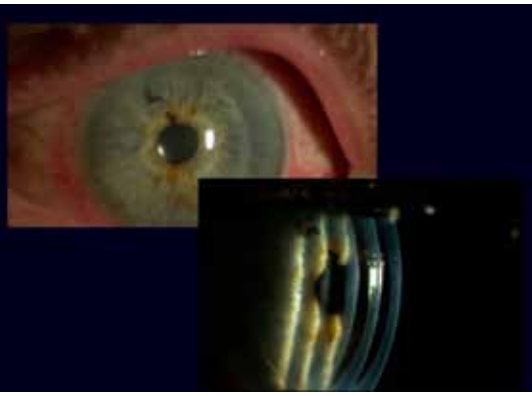

DSAEK ISSUES

- DISLOCATION
  - Good air Fill
  - No Healon
  - Technique
- ENDOTHELIAL FAILURE
- Technique

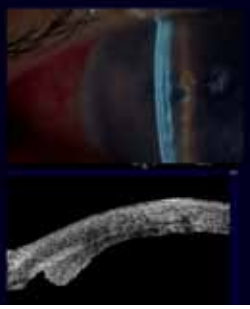

DSAEK ISSUES

- ENDOTHELIAL FAILURE - avoidance
  - Young Donor preferable
  - Single point fixation of Folded Donor
  - Increase incision size

'DALK and Endothelial Keratoplasty'

(slides 17-32)

Sheraz Daya
MD FACP FRCS(Ed) FRCOphth

Descemet's Membrane Endothelial Keratoplasty (DMEK)

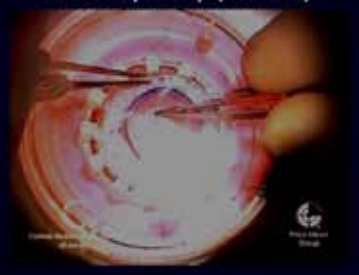

INTRALASE
and Corneal Grafting

Intralase & Corneal Grafts

- Intralase Femtosecond Laser
  - CE marked for making PRECISE cuts in corneal tissue
  - Principally used for Flap creation in Lasik
  - Applications in Grafting
    - Anterior Lamellar Keratoplasty
    - Posterior Lamellar Keratoplasty (DSIEK)
    - Penetrating Keratoplasty

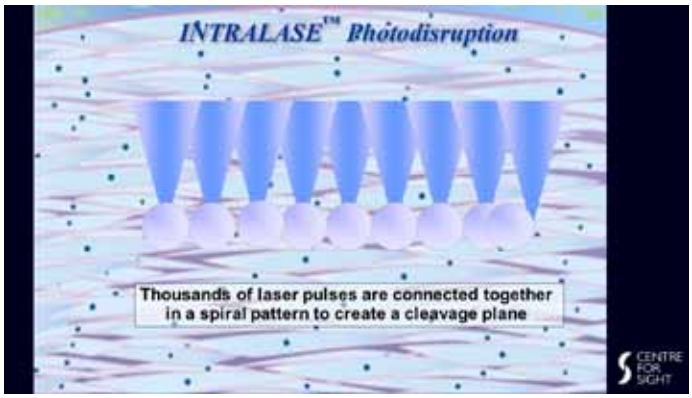

Anterior Lamellar Keratoplasty

LAMELLAR GRAFTS

- Anterior Basement Membrane Dystrophy – Familial

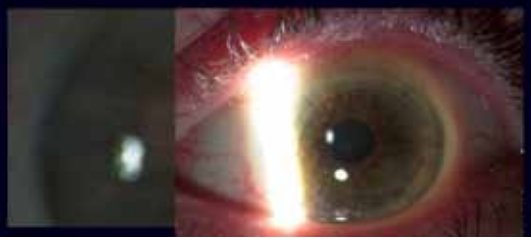

HISTOLOGY



CENTRE FOR SIGHT

RESULTS

- BSCVA
  - One eye = Amblyopic (improved from 20/200 to 20/100) excluded

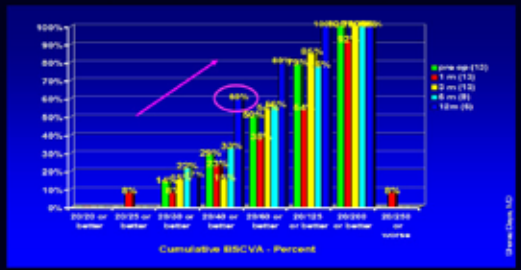

CENTRE FOR SIGHT

RESULTS

- BSCVA - lines gained /lost

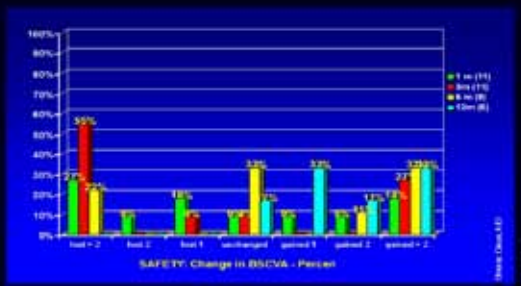

CENTRE FOR SIGHT

RESULTS - Keratometric Astigmatism

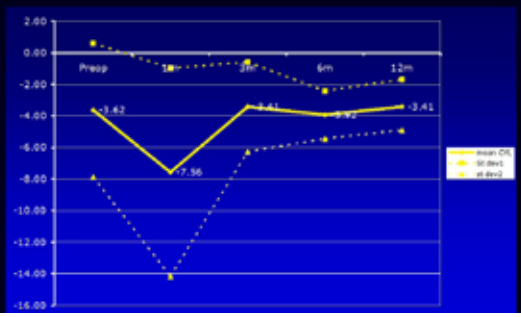

CENTRE FOR SIGHT

Complications

- Compression Striae -recovered following suture removal
- Replacement in one case
  - Polyopia and high astigmatism (graft oversized)
- Residual refractive error
  - May need supplemental LASIK

CENTRE FOR SIGHT

GEOMETRIC PATTERNS - I

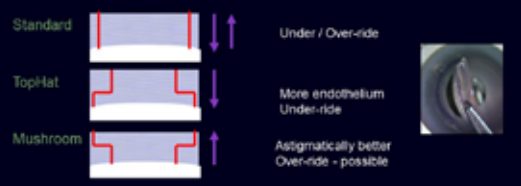

CENTRE FOR SIGHT

GEOMETRIC PATTERNS - II

- "Tongue & Groove" !

- STABLE - no OVER or UNDER riding
- ANTERIOR ANGLE (ZIG) = smooth anterior join / surface

CENTRE FOR SIGHT

Femtosecond PK

CENTRE FOR SIGHT

ZIG- SQUARE
(recipient button)

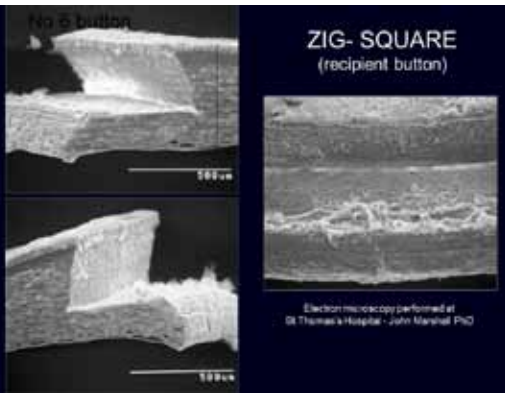

CENTRE FOR SIGHT

'DALK and Endothelial Keratoplasty
(slides 33-48)

Sheraz Daya
MD FACP FRCS(Ed) FRCOphth

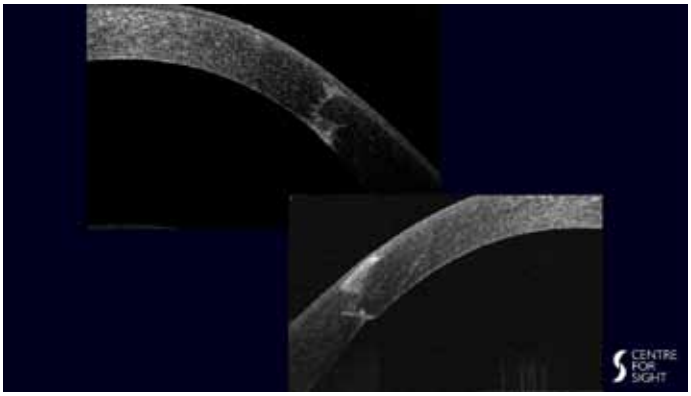

ZIG-SQUARE

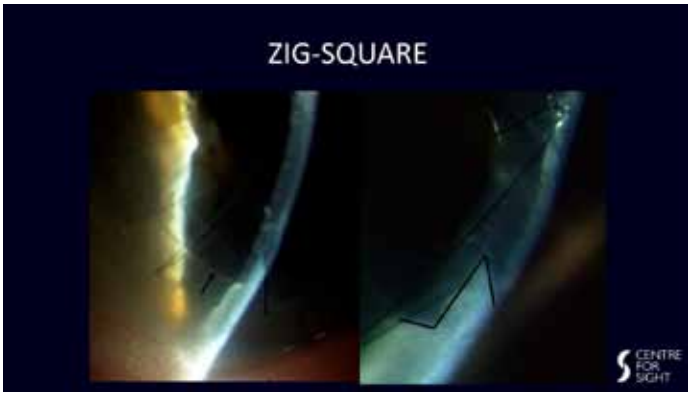

INTRALASE PK - 6 months

Endothelial Cell Count

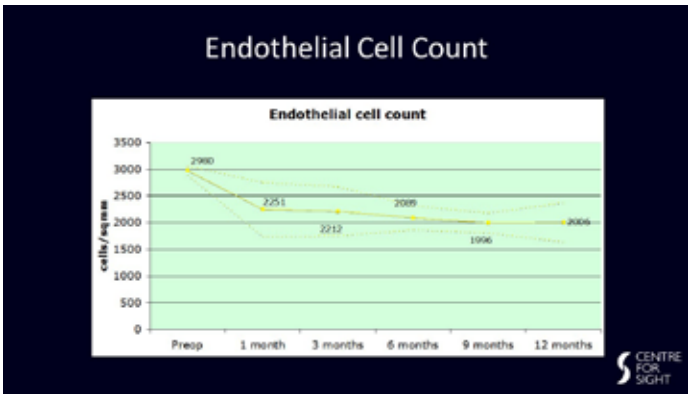

INTRALASE PK - BSCVA

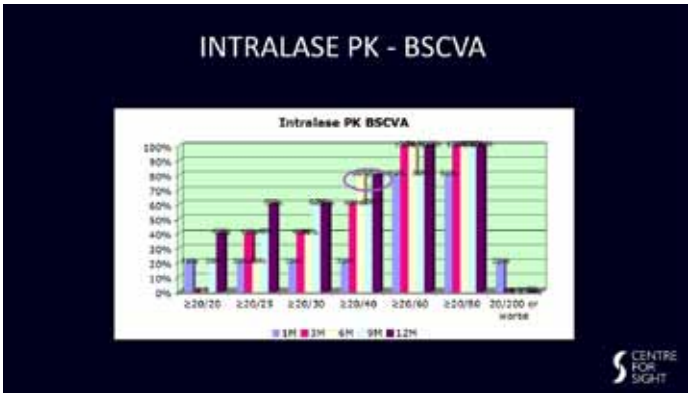

ASTIGMATISM

Spherical Equivalent



Penetrating Keratoplasty

- INDUSTRY Involvement
  - Improved biomechanical strength
    - Inverse cut
    - Tophat cuts

  - Better astigmatic outcomes

CENTRE FOR SIGHT

FEMTOSECOND DALK

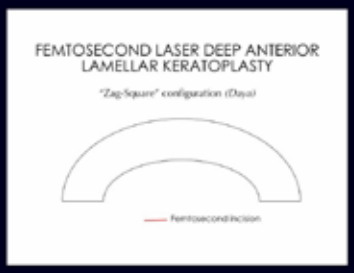

CENTRE FOR SIGHT

FSDALK – Donor Preparation

CENTRE FOR SIGHT

FSDALK - Recipient

CENTRE FOR SIGHT

Postoperative 6 weeks

CENTRE FOR SIGHT

Conclusion

- Selective Keratoplasty
  - Superficial Anterior Lamellar Keratoplasty
    - Microkeratome
    - Femtosecond Laser
  - Deep Anterior Lamellar Keratoplasty
    - Manual
    - Big bubble
    - Femtosecond laser

CENTRE FOR SIGHT

Thank you

CENTRE FOR SIGHT

'DALK and Endothelial Keratoplasty'

(slides 49-54)

Sheraz Daya
MD FACP FRCS(Ed) FRCOphth