17

Keratoconus Update

Diagnosis of Keratoconus

Sheraz Daya
MD FACP FRCS(Ed) FRCOphth

CENTRE FOR SIGHT

Diagnosis of Keratoconus

SHERAZ M. DAYA
MD FACP FACS FRCSE

CENTRE FOR SIGHT

Anatomy of the normal cornea

- Epithelium 75 microns
- Bowman's layer 10 microns
- Stroma 450 microns
- Descemet's membrane 10 microns
- Endothelium 5 microns

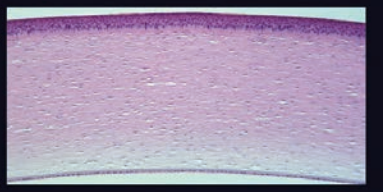

CENTRE FOR SIGHT

Collagen





CENTRE FOR SIGHT

Anterior stroma structure



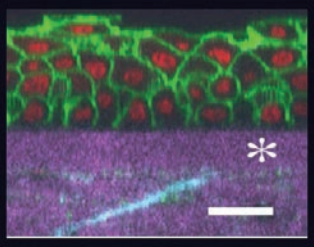

Jester et al.

CENTRE FOR SIGHT

Posterior stromal structure



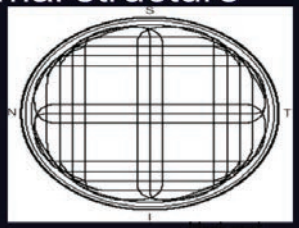

CENTRE FOR SIGHT

Keratoconus

Defined:

- Progressive, non-inflammatory thinning disorder of the cornea, leading to altered shape adversely affecting visual performance
- Variety of ectasias
  - Keratoconus
  - Pellucid Marginal Degeneration
  - Keratoglobus

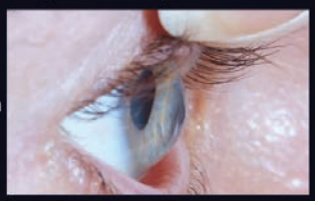

Keratoconus

•Keratoconus Facts

- 50 to 230 cases per 100,000
- Strong association with Atopy
- Why ?
  - Inflammation, influences elasticity ?
  - Eye Rubbing
- Definite rationale for:
  - Aggressive treatment of Allergic Conjunctivitis
    - Mast cell stabilisers
    - Steroids

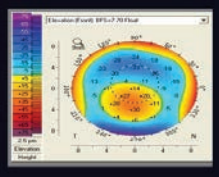

CENTRE FOR SIGHT

Keratoconus

- Asymmetric
- Usual onset during puberty
- Progressive myopia + irregular astigmatism
- Corneal thinning with conical deformation
- Association
  - Atopy
  - eye rubbing
  - Down's syndrome
  - Marfan's syndrome

CENTRE FOR SIGHT

'Diagnosis of Keratoconus'

(slides 1-8)

Sheraz Daya
MD FACP FRCS(Ed) FRCOphth

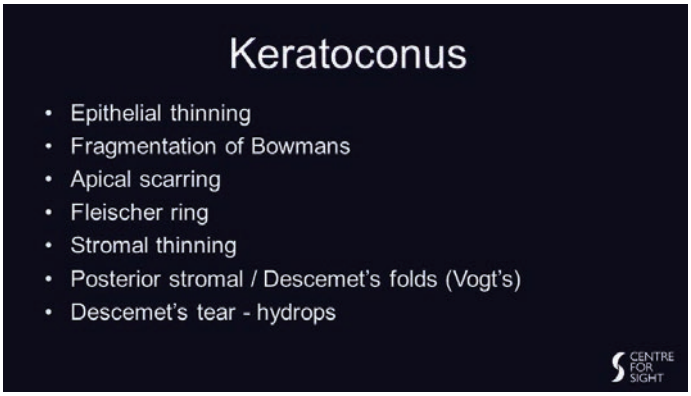

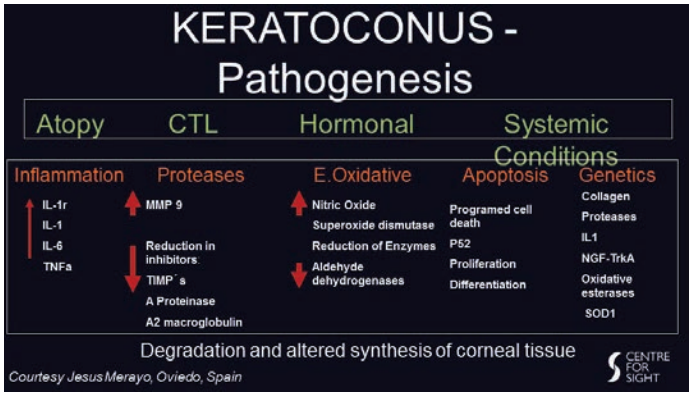

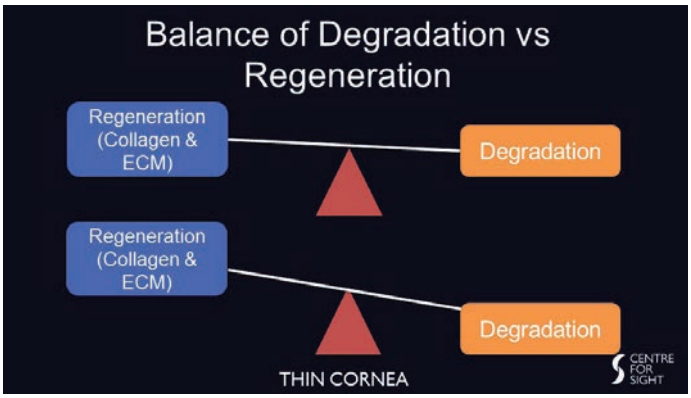

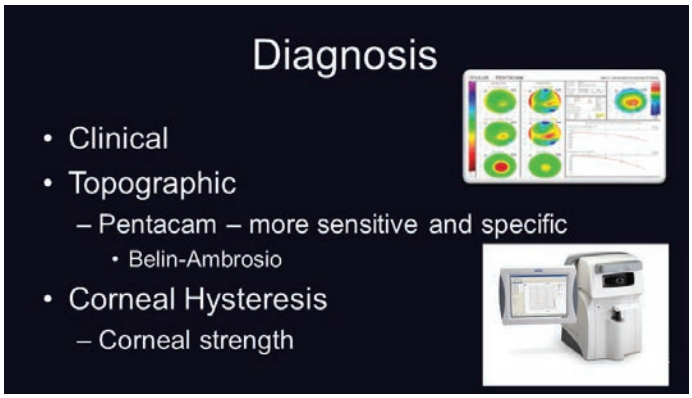

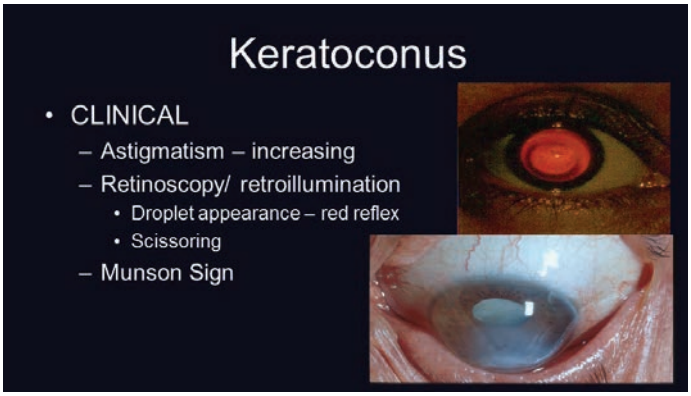

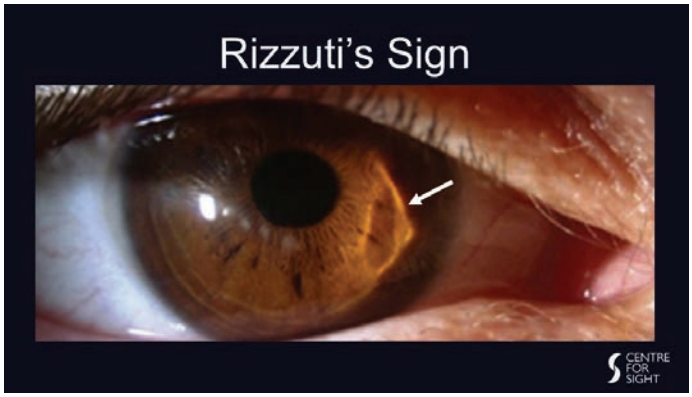

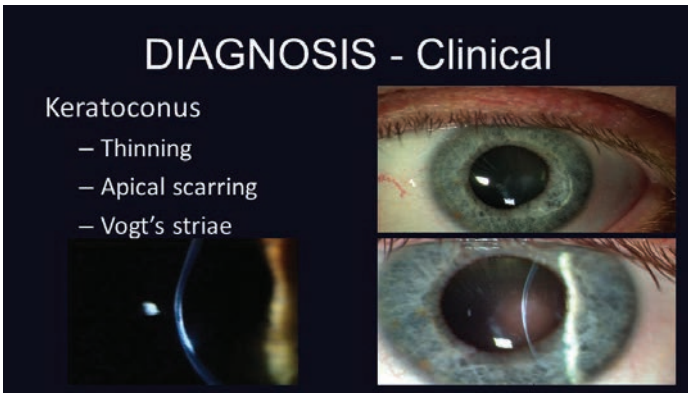

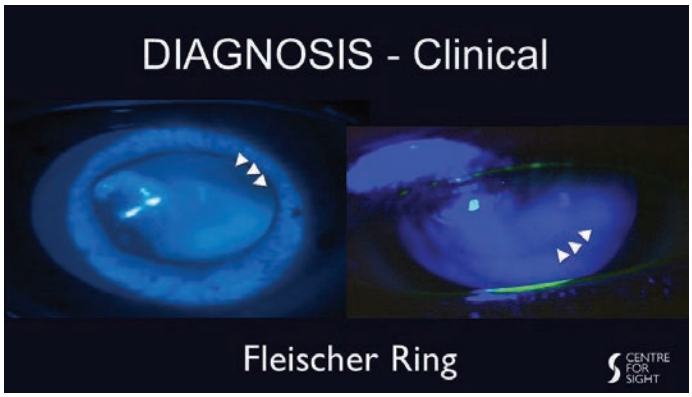

'Diagnosis of Keratoconus'

(slides 9-24)

Sheraz Daya
MD FACP FRCS(Ed) FRCOphth

Vogt's Striae

Hydrops

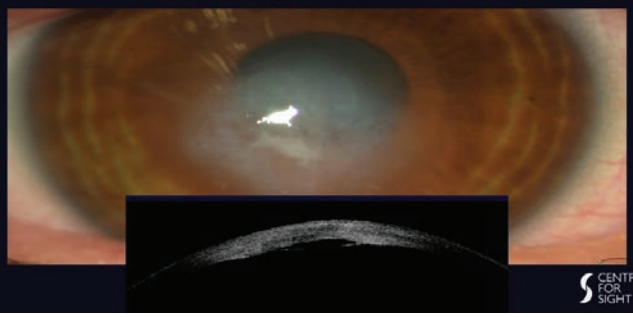

Pellucid Marginal Degeneration

Keratoglobus

DIAGNOSIS: Corneal Topography

- Steep cornea
- Non- orthogonal astigmatism
- Inferior Steepening
- Coinciding point:
  - Anterior elevation
  - Posterior elevation
  - Thinnest spot on cornea



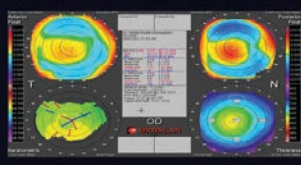

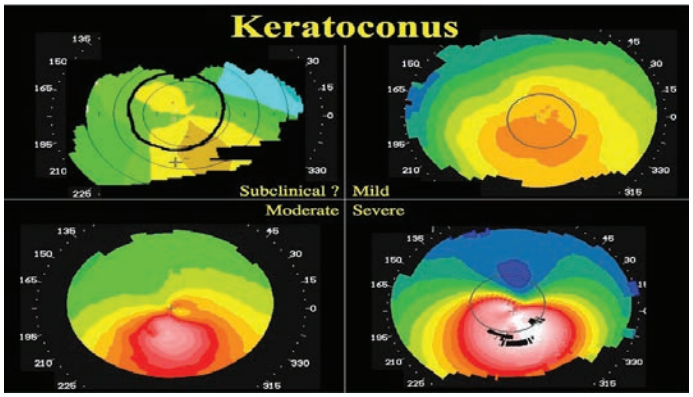

3-Dimensional Topography

- Slit beam – Orbscan
- Scheimpflug
  - Pentacam *(Oculus)*
  - Gallilei *(Zeimar)*
  - Sirius *(CSO)*
- OCT
  - Casia 2 *(Tomey)*
  - MS 39 *(CSO)*
  - Antereon *(Heidelberg)*

Scanning slits measure several surfaces



CENTRE FOR SIGHT

Scheimpflug imaging

- Pentacam (Oculus, Inc)
- Two integrated cameras:
  - Central: size and orientation of the pupil, and fixation
  - Rotating Scheimpflug camera
- 50 Scheimpflug images during one scan in less than 2 seconds

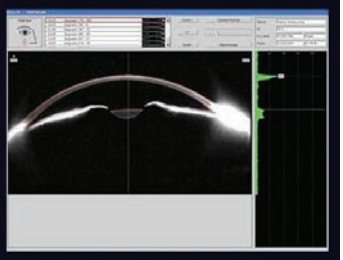

CENTRE FOR SIGHT

Scheimpflug imaging

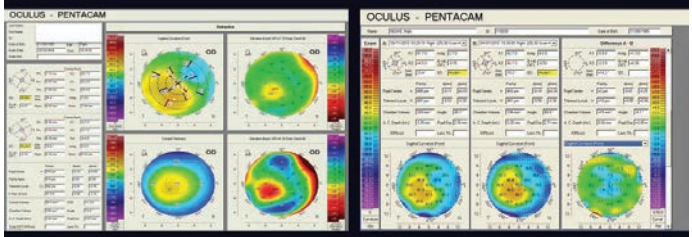

CENTRE FOR SIGHT

Ultrasound digital topography

- High-frequency ultrasound scanning
- Thickness of corneal layers with high precision.
- Post refractive surgery.
- Not limited to optically transparent tissue.

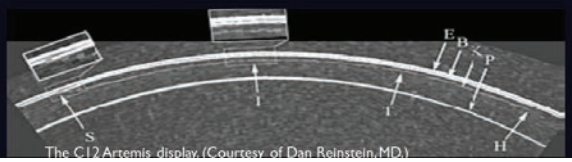

The C12 Artemis display. (Courtesy of Dan Reinstein, MD.)

CENTRE FOR SIGHT

Corneal Biomechanics

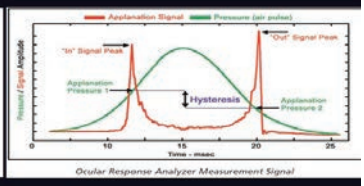

Ocular Response Analyzer Measurement Signal

CENTRE FOR SIGHT

CORVIS - Corneal Deformation

KERATOCONUS

Deforms earlier
Increased
- Deformation
- Oscillation



Courtesy Renato Ambrosio

Keratoconus Diagnosis

- Clinical
  - Oblique or ATR astigmatism
  - Increasing astigmatism
  - Scissoring
- Diagnostics
  - 3-D tomography – gold standard
  - Hysteresis - useful

CENTRE FOR SIGHT

Treatment options

TRADITIONAL
- Spectacles
- Contact lenses
  - Soft ; toric; RGP;
- Corneal graft
  - Penetrating keratoplasty
  - Lamellar keratoplasty

CENTRE FOR SIGHT

Management of Keratoconus 2017

- Collagen Crosslinking (CXL)
  - +/- topo guided PRK
- Intracorneal Rings
- Myoring
- Toric Phakic Lenses (ICL or Artisan)
- Corneal Transplantation

CENTRE FOR SIGHT

'Diagnosis of Keratoconus'

(slides 25-32)

Sheraz Daya
MD FACP FRCS(Ed) FRCOphth

Keratoconus Update

Corneal Collagen CrossLinking for Keratoconus

Marcela Espinosa
MD

CENTRE FOR SIGHT

Collagen Crosslinking for Keratoconus



Marcela Espinosa-Lagana MD

CENTRE FOR SIGHT

Collagen Crosslinking (CXL)

- Riboflavin
  - Large Molecule
  - Does not penetrate epithelial tight junctions
- Traditional Method of CXL
  - Epithelial Removal
- Transepithelial CXL
  - Tetracaine
  - Transepithelial Riboflavin solutions
- Epithelial Disruption CXL
  - Alternative option
  - Breaks in epithelium allow Riboflavin to penetrate

CENTRE FOR SIGHT

Collagen



Collagen Fibril
- Triple helix

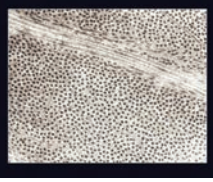

CENTRE FOR SIGHT

Collagen Cross Linking

Natural
- Ageing

Pathogenic
- Diabetes Mellitus – chronic hyperglycaemia

Artificial
- Strengthen collagenous valves - Cardiac Surgery
- Cornea for Keratoconus !

CENTRE FOR SIGHT

Collagen Cross Linking

•Mechanism
- Riboflavin
- UVA light exposure
- Formation of free radicals
- Oxidation reaction with development of cross-links in collagen

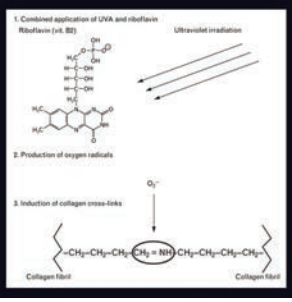

CENTRE FOR SIGHT

Cross Linking

- Increases Tensile rigidity in Human Cornea by 328% (stress testing)
- Young's Modulus increases 4.5 times

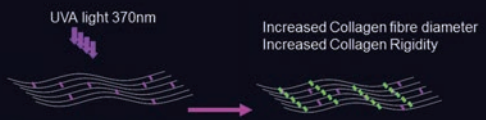

Wollensak et al. Stress strain measurements of human and porcine corneas after riboflavin-ultraviolet A-induced cross linking. J Cataract and Refract Surg 2003; 29: 1780-1785

CENTRE FOR SIGHT

Basic research

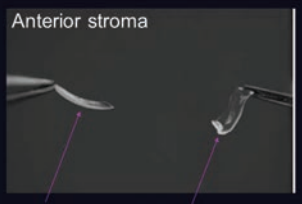

Treated CCL

Untreated

Pillunat et al.

CENTRE FOR SIGHT

Epithelial Disruption - Method

Topical Anaesthesia
Topical Antibiotic
Topical Pilocarpine (2%)

Epithelial Disruption (Daya Disruptor)
Riboflavin instillation (45 mins)

Check penetration at Slit Lamp

Bandage Lens

CENTRE FOR SIGHT

'Corneal Collagen CrossLinking'

(slides 1-16)

Marcela Espinosa
MD

Corneal "Cross linking"

UV light exposure (370nm)
3mW/cm2
Variable aperture
30 minutes

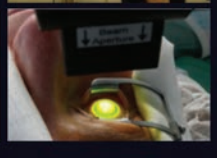

CENTRE FOR SIGHT

RESULTS - different

Bandage CTL – removed by 48 hours

Persistent Epithelial Defect	0
Infectious Keratitis	0
Sterile Infiltrates	0
Pain – day of procedure	111

Demarcation line or Anterior Haze 61%

CENTRE FOR SIGHT

Safety

Corneal thickness must be 400µm

If thinner use riboflavin without dextran

Measure before treatment!



Irradiance is reduced by 95% at endothelium

CENTRE FOR SIGHT

Postop CXL – 1 month

CENTRE FOR SIGHT

CXL – 1 month postop Demarcation

61%

CENTRE FOR SIGHT

Corneal "Cross Linking"

- Retrospective Study
- Keratoconus
- Analysis of Results Centre for Sight
- 154 Consecutive eyes 2011-2016

CENTRE FOR SIGHT

Corneal "Cross Linking"

- Retrospective Study
- Keratoconus
- Analysis of Results Centre for Sight
- 154 Consecutive eyes 2011-2016

CENTRE FOR SIGHT

Collagen Crosslinking (CXL)

Procedures

- 30min UV exposure 41 procedures
  - 39 Epithelial disruption
  - 2 Epithelial removal
- 10min UV exposure 113 procedures
  - 63 Epithelial disruption
  - 50 Epithelial removal

CENTRE FOR SIGHT

CENTRE FOR SIGHT

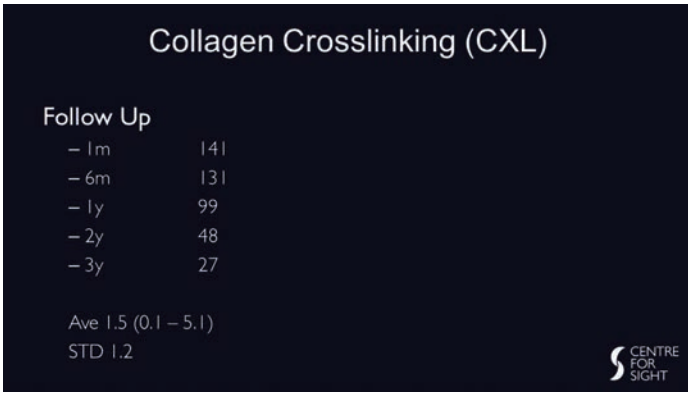

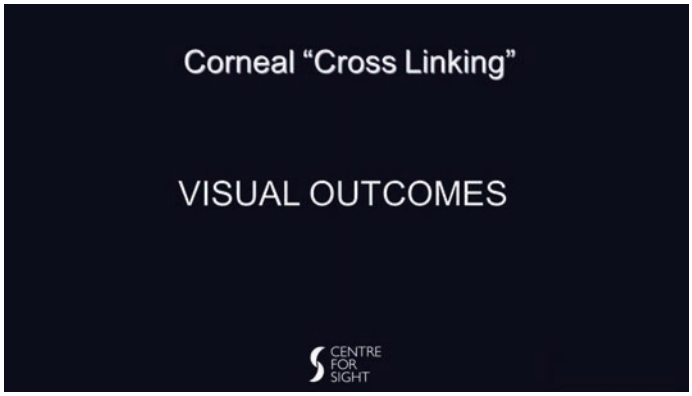

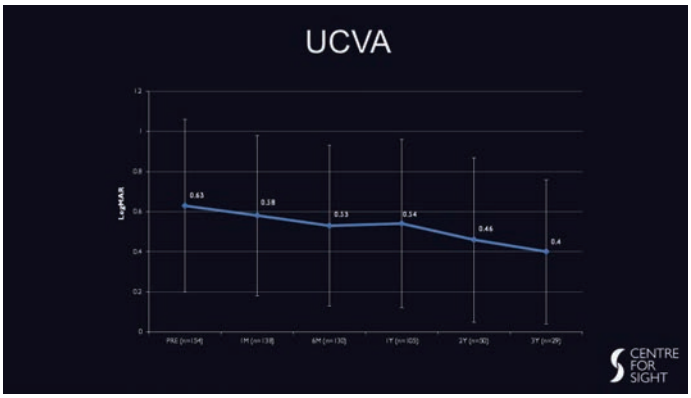

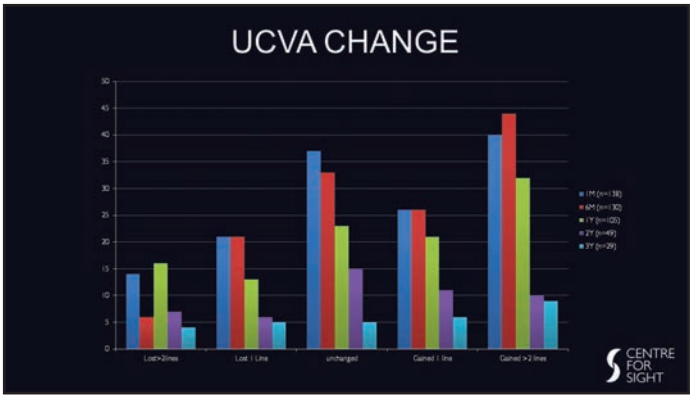

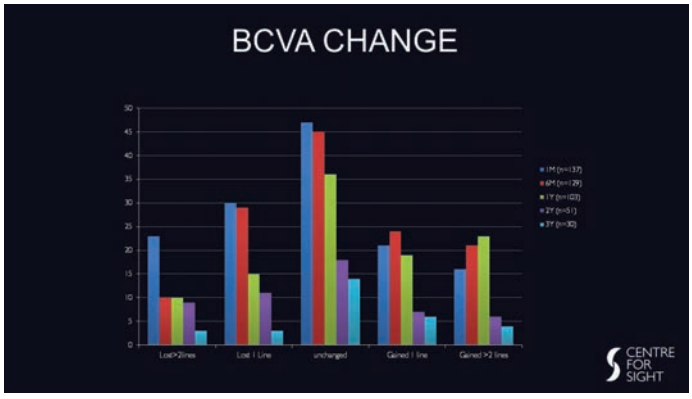

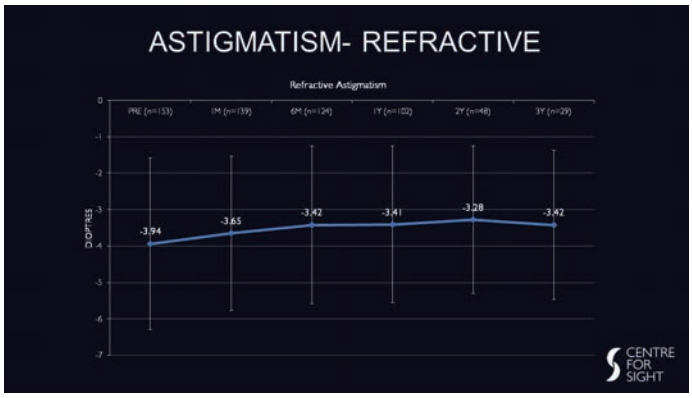

'Corneal Collagen CrossLinking'

(slides 17-30)

Marcela Espinosa
MD

KERATOMETRIC EVOLUTION (PENTACAM)

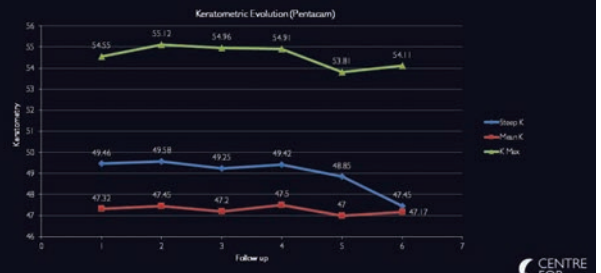

CENTRE FOR SIGHT

STEEPEST KERATOMETRY (PENTACAM)

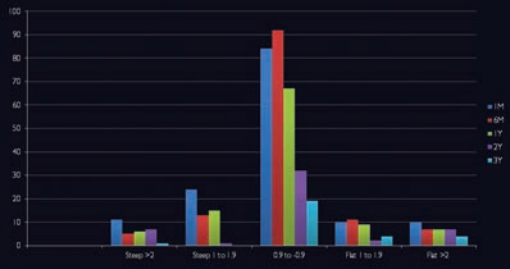

CENTRE FOR SIGHT

MEAN KERATOMETRY (PENTACAM)

CENTRE FOR SIGHT

KMAX CHANGE (PENTACAM)

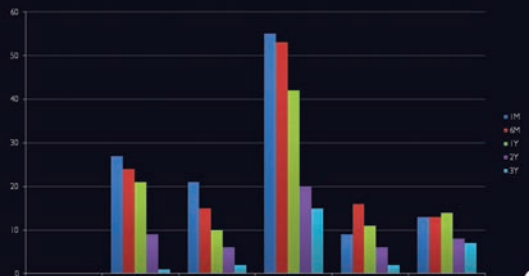

CENTRE FOR SIGHT

RESULTS

- Bandage CTL – removed by 48 hours

- Persistent Epithelial Defect 0
- Infectious Keratitis 0
- Sterile Infiltrates 0
- Pain – day of procedure

- Demarcation line or Anterior Haze 61%

CENTRE FOR SIGHT

Thank you

CENTRE FOR SIGHT

CENTRE FOR SIGHT

27

Keratoconus Update

Intracorneal rings for Keratoconus

Sheraz Daya
MD FACP FRCS(Ed) FRCOphth

CENTRE
FOR
SIGHT

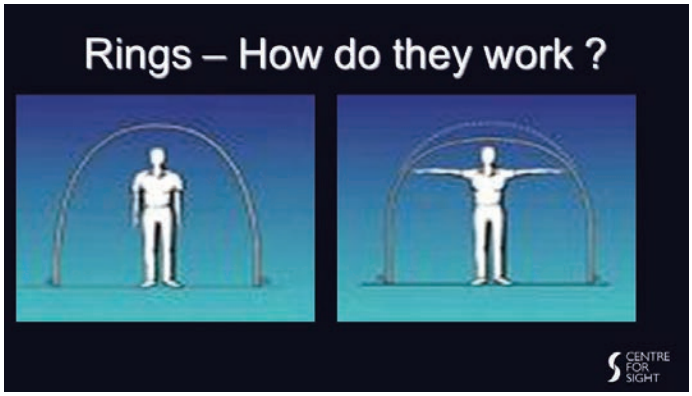

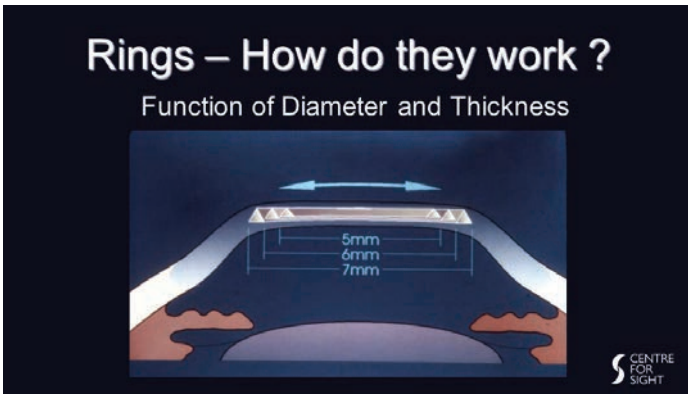

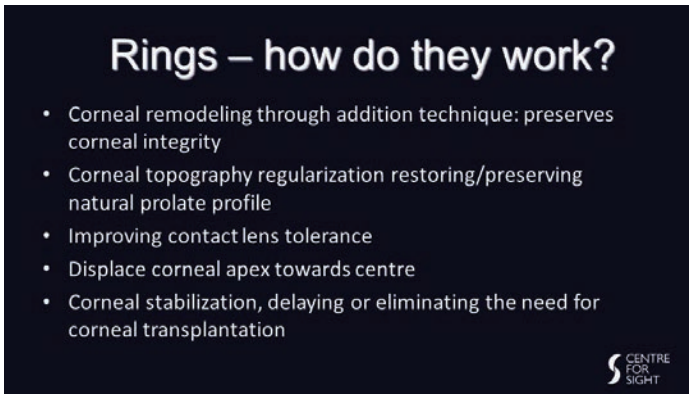

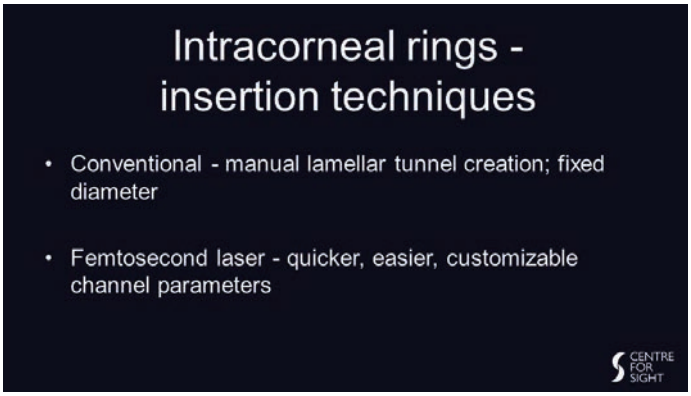

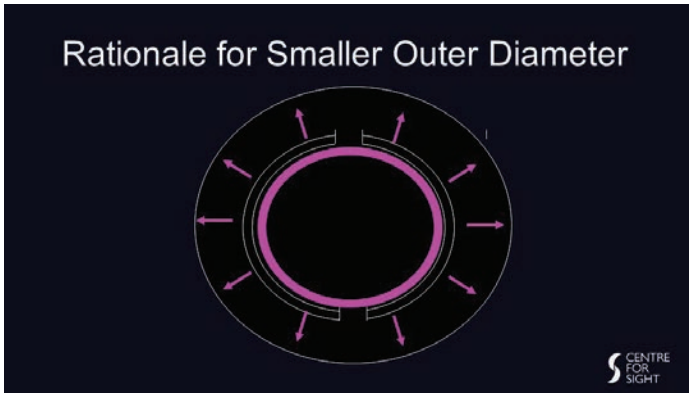

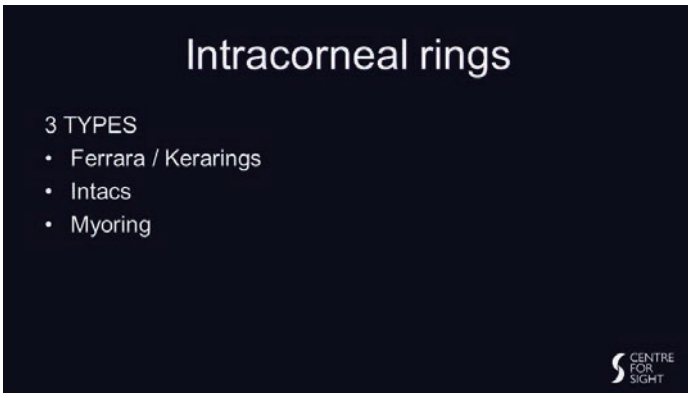

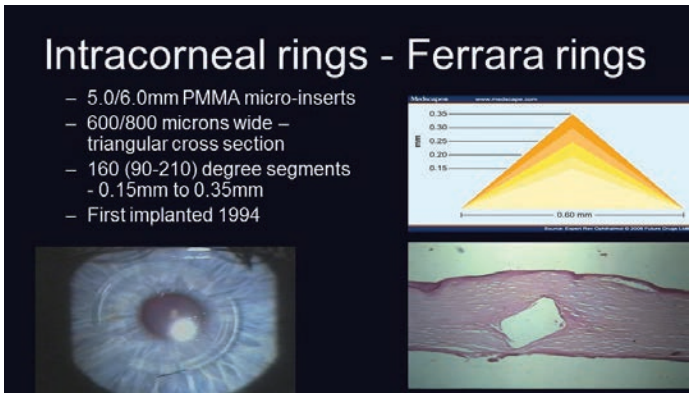

'Intracorneal Rings for Keratoconus'

(slides 1- 8)

Sheraz Daya
MD FACP FRCS(Ed) FRCOphth

Ferrara Ring - Prismatic Effect

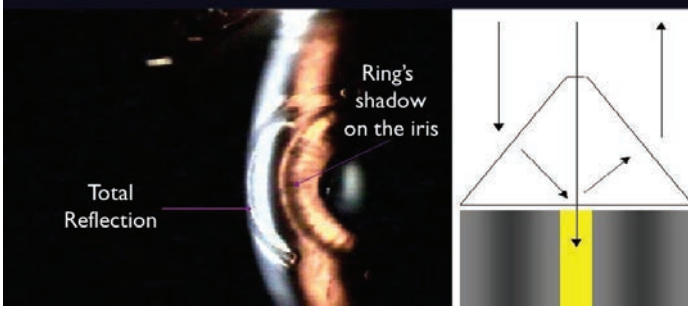

Intracorneal rings - INTACS

- 7mm diameter PMMA micro-inserts
- 6.0mm (SK)
- 150-210 degree segments - 0.21mm to 0.45mm
- Hexagonal cross section
- Can treat corneas up to 55D



Intracorneal rings - INTACS SK

- Smaller - 6mm diameter PMMA micro-inserts
- 90 to 150 degree segements - 0.21mm to 0.50mm
- For more severe cases – up to 62D
- Elliptical profile

Intracorneal rings - indications

- Spectacle / contact lens intolerance
- Keratometry up to 62D
- Clear visual axis
- Pachymetry > 400 microns

Intracorneal rings - indications

- MUST HAVE REALISTIC EXPECTATIONS
- Aim is to restore contact lens tolerance and improve BCVA - NOT UCVA
- Long recovery period – fluctuating vision for up to 18 months

Intracorneal rings - procedure

- Daycase / Topical anaesthesia
- Bandage contact lens for 24hrs
- Topical triple therapy for 1 month
  - G. Chloramphenicol Q2H
  - G. Levofloxacin Q2H
  - G. FML qds tapering by one drop weekly

Intralase Insertion of Intacs

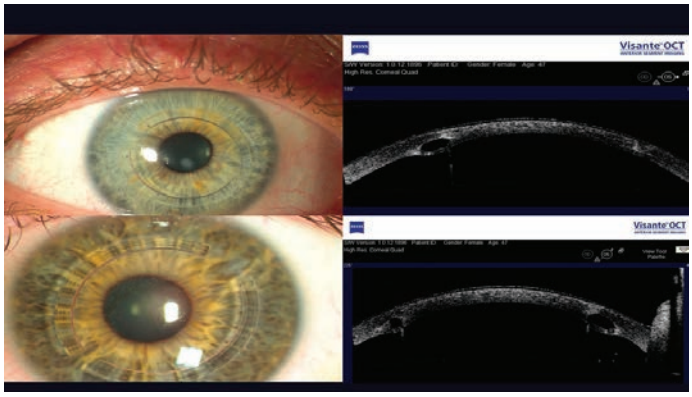

'Intracorneal Rings for Keratoconus'

(slides 9-24)

Sheraz Daya
MD FACP FRCS(Ed) FRCOphth

INTACS - complications

- Infection
- Extrusion
- Perforation - mechanical > femto
- Channel deposits
- Inadequate effect

CENTRE FOR SIGHT

Infection

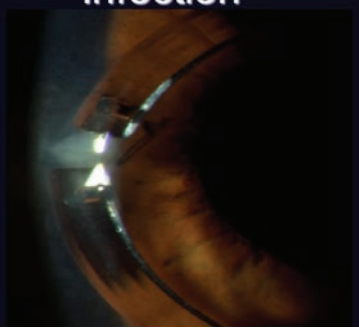

CENTRE FOR SIGHT

Infection

Extrusion

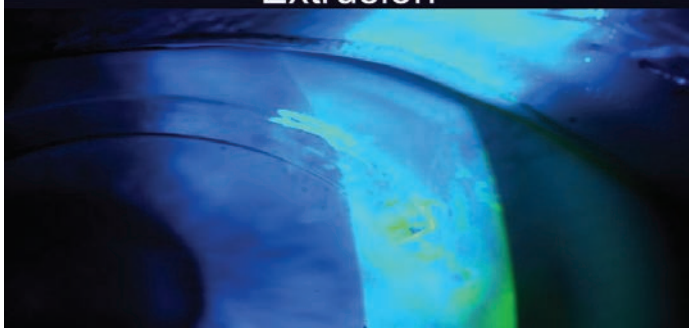

Channel deposits

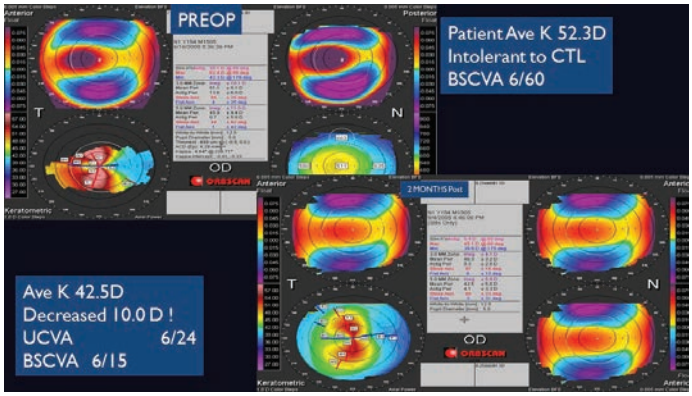

Results - Change In Keratometry

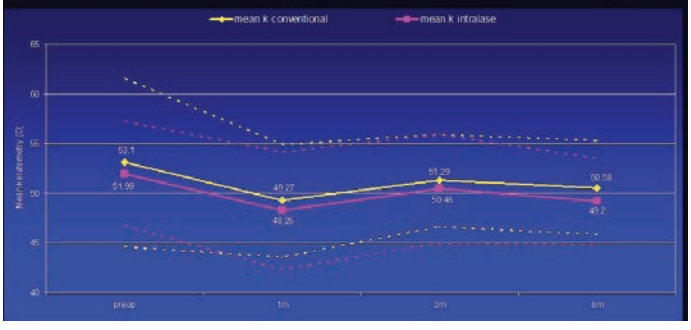

Results - Mean Refractive Cylinder

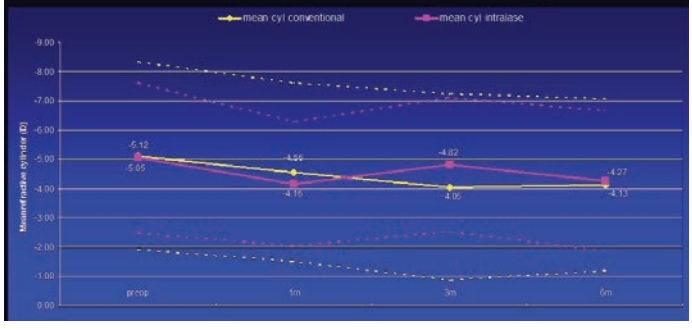

CENTRE FOR SIGHT

Results - Spherical Equivalent

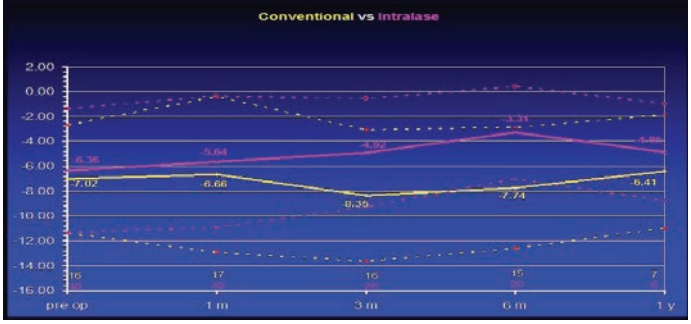

Results - BSCVA -mechanical

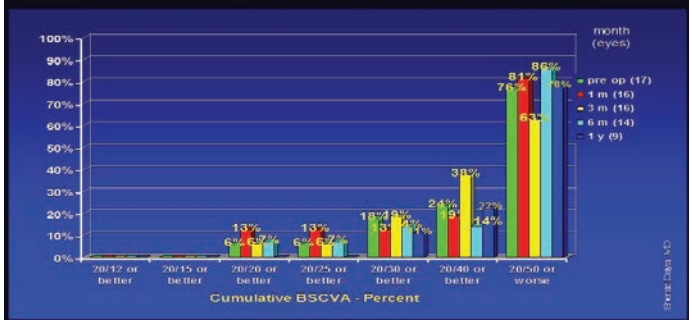

Results - BSCVA - Femtosecond

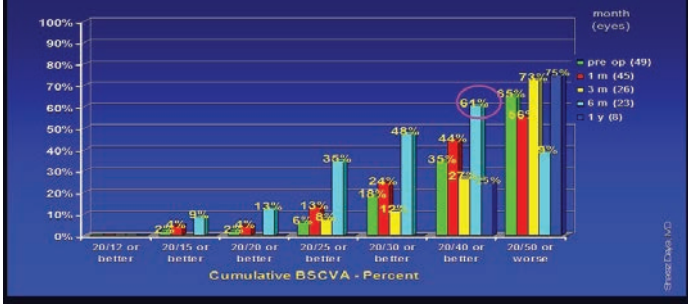

RESULTS - Ferrara literature

	BSCVA	MEAN KERATOMETRY	MEAN REF CYL	SPHERICAL EQUIV
PESANDO ET AL EUR J OPHTH 2010 130 EYES	Improved in 97.6%	Decreased by 4.59D		Decreased by 5.51D
FERRARA +TORQUETTI JCRS 2009 80 EYES	Improved in 86.4%	Decreased by 4.64D		Decreased by 2.96D
KWITKO/SEVERO JCRS 2004 51 EYES	Improved in 86.4%	Decreased by 5.59D	Decreased by 1.66D	Decreased by 1.53D
MIRANDA ET AL JRS 2003 36 EYES	Improved in 80.6%	Decreased by		Decreased by 2.49D

CENTRE FOR SIGHT

Results - INTACS literature

	BSCVA	MEAN KERATOMETRY	MEAN REF CYL	SPHERICAL EQUIV
SANSANAYUDH ET AL JCRS 2010 10 EYES - SK	Mean improved from -0.51 to -0.24 logmar	Decreased by 7.87D	Decreased by 1.15D	Decreased by 3.05D
RODRIGUEZ ET AL JRS 2009 7 EYES - SK	Improved in 86.4%	Decreased by 5.23D	Decreased by 1.66D	Decreased by 11.74D
WACHLER ET AL OPHTHALMOLOGY 2003 12 EYES	Improved in 45%			Decreased by 1.53D
J COLIN JCRS 2006 57 EYES	Improved by 2 lines or more in 63%	Decreased by 3.7D	Decreased by 2.94D	Decreased by 2.49D

CENTRE FOR SIGHT

Intracorneal rings - conclusions

Improves contact lens tolerance and BSCVA

Reduction in SE, Mean K & Astigmatism

Femtosecond better than mechanical

CENTRE FOR SIGHT

Intracorneal rings

- Can be performed in conjunction with CXL
  - Early data
    - MORE effect
    - Less fluctuation

CENTRE FOR SIGHT

Thank you !

CENTRE FOR SIGHT

'Intracorneal Rings for Keratoconus'

(slides 25-32)

Sheraz Daya
MD FACP FRCS(Ed) FRCOphth

Keratoconus Update

Phakic Intraocular Lenses

Sheraz Daya
MD FACP FRCS(Ed) FRCOphth

CENTRE FOR SIGHT

PHAKIC INTRAOCULAR LENSES



SHERAZ DAYA
MD FACP FACS FRCS(Ed)

CENTRE FOR SIGHT

LENS SURGERY

- Additive
- Reversible
- Optically – advantageous
  - Hyperopia / Myopia
  - Toricity
  - ? Future – Multifocality
- Astigmatism
  - Application in KERATOCONUS

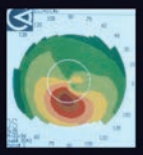

CENTRE FOR SIGHT

INDICATIONS

- Any Refractive Error
  - Myopia to -18.00 (ICL), Artisan (-23.00)
  - Hyperopia to +10.00 (ICL), Artisan (+12.00)
  - Astigmatism 6.00D
- AC Depth > 2.8mm
- Endothelial Cell Count >2000 cells/mm^2
- KERATOCONUS
  - Stable Refraction
  - Good Refraction with Glasses

CENTRE FOR SIGHT

PHAKIC IOL - Options

- VISIAN ICL
  - implantable contact lens

- ARTISAN / ARTIFLEX
- (Veriseyes/Veriflex)

CENTRE FOR SIGHT

Anterior Segment Biometry

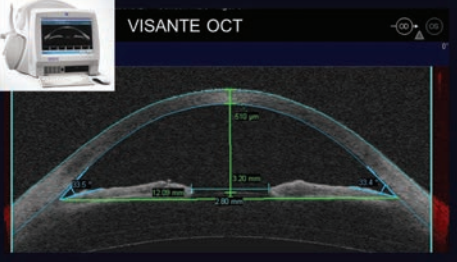

CENTRE FOR SIGHT

STS Ultrasound Biomicroscopy

CENTRE FOR SIGHT

ARTISAN/ARTIFLEX IOL

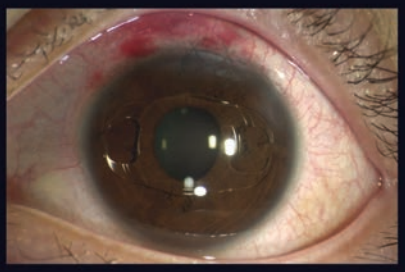

CENTRE FOR SIGHT

ARTISAN Toric IOL
AXIS of Toricity 90 or 180

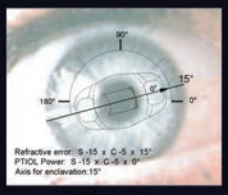

PTIOL - 0

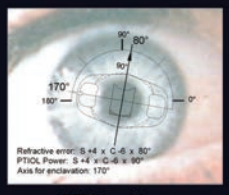

PTIOL - 90

CENTRE FOR SIGHT

'Phakic Intraocular Lenses'

(slides 1-16)

Sheraz Daya
MD FACP FRCS(Ed) FRCOphth

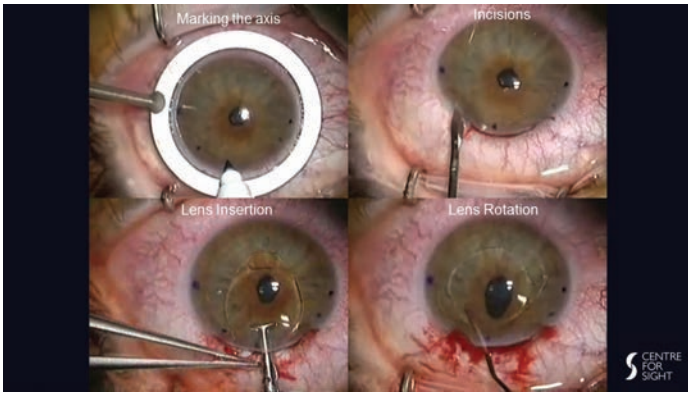

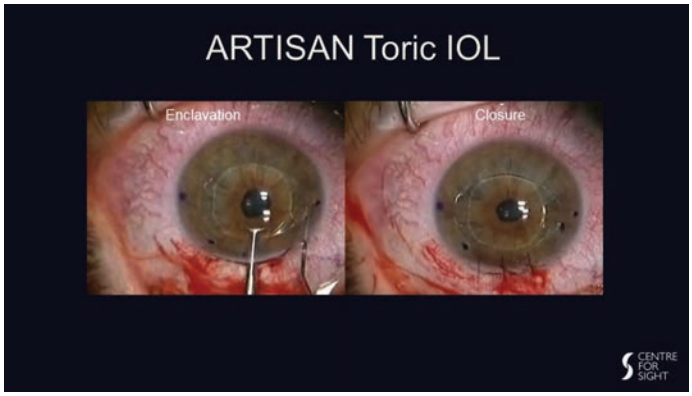

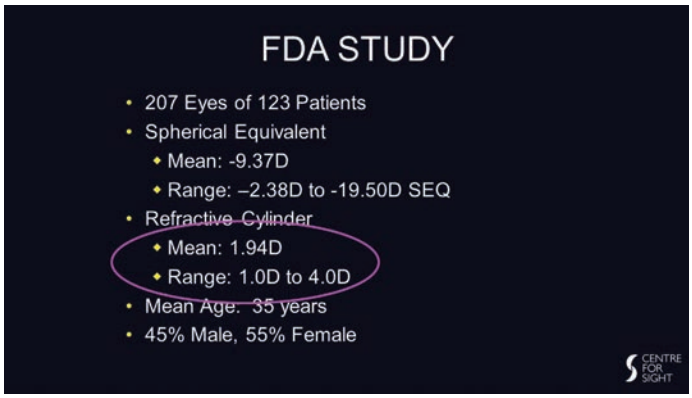

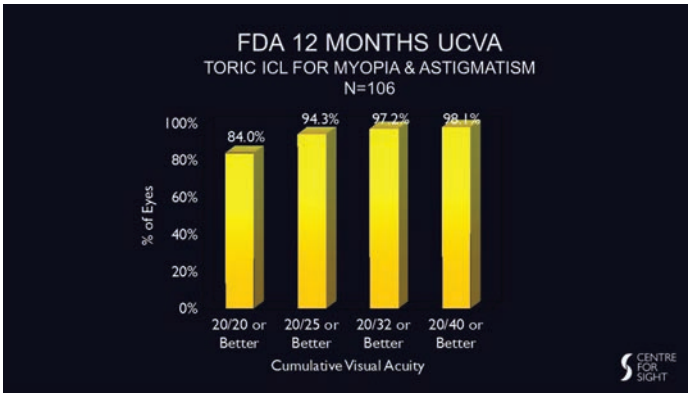

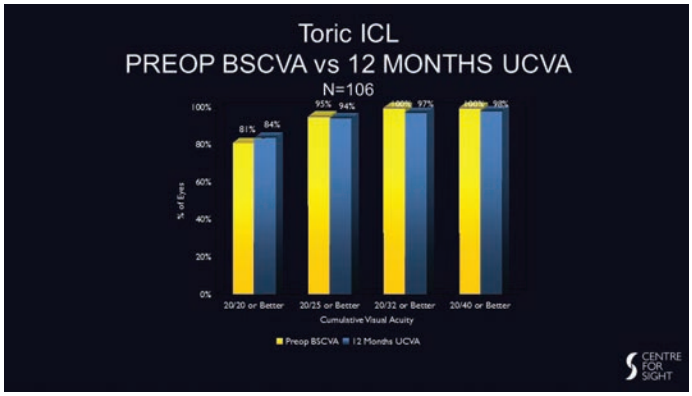

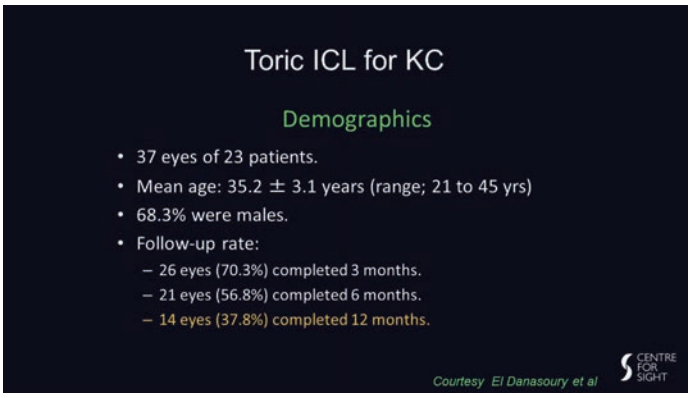

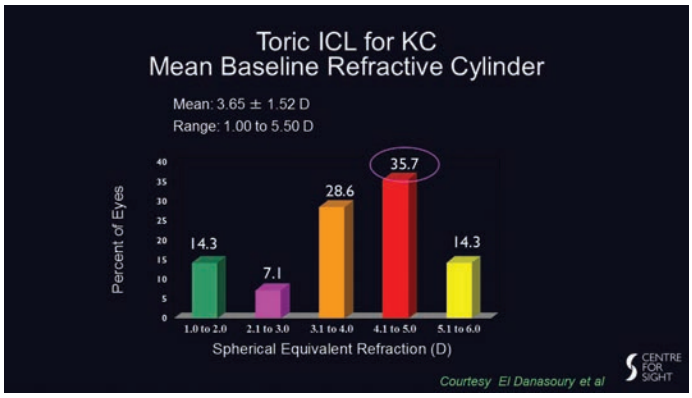

CENTRE FOR SIGHT

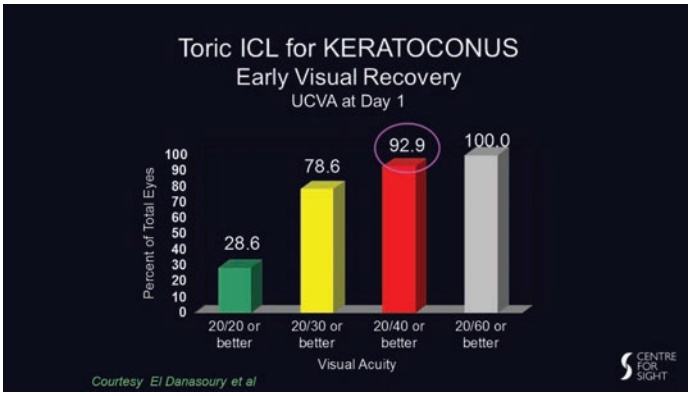

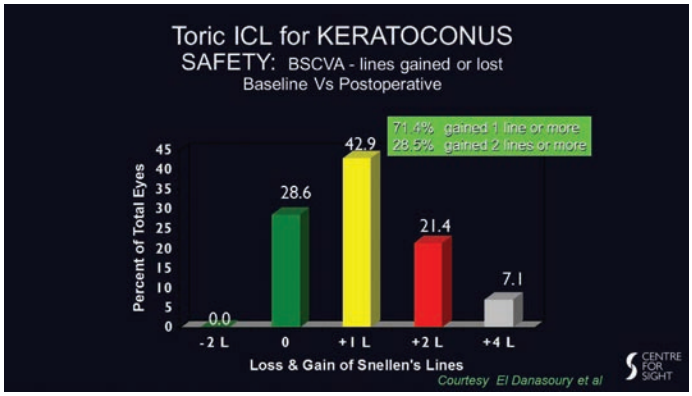

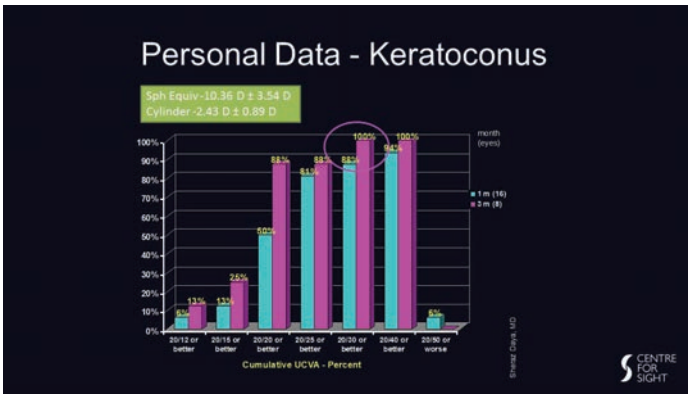

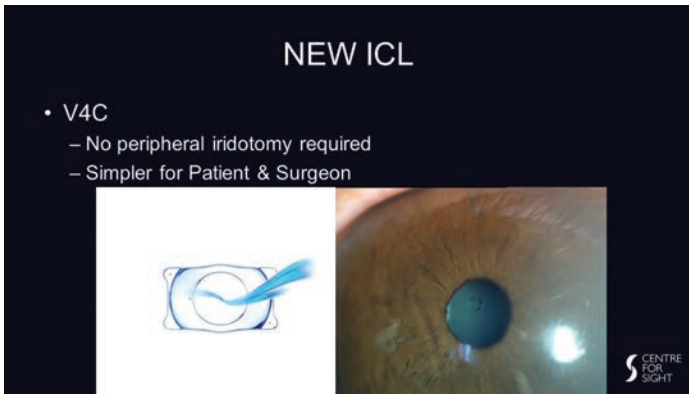

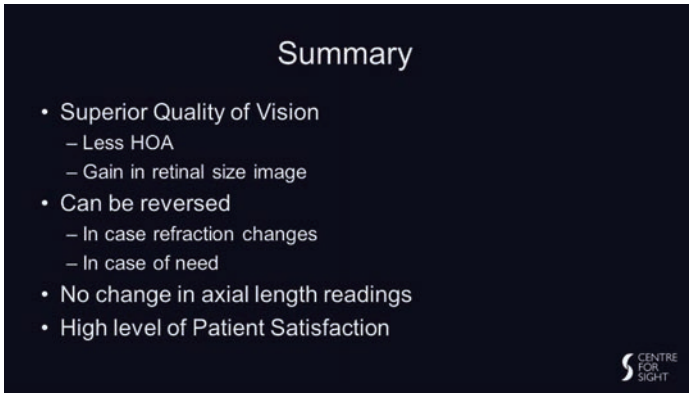

'Phakic Intraocular Lenses'

(slides 17-23)

Sheraz Daya
MD FACP FRCS(Ed) FRCOphth

Keratoconus Update

Keratoconus - An Algorithmic approach

Sheraz Daya
MD FACP FRCS(Ed) FRCOphth

CENTRE FOR SIGHT

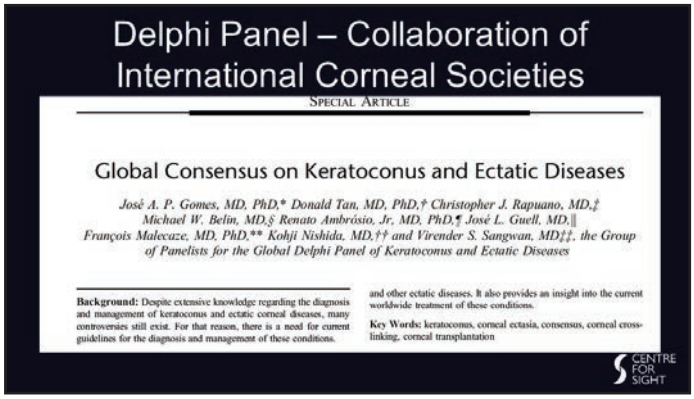

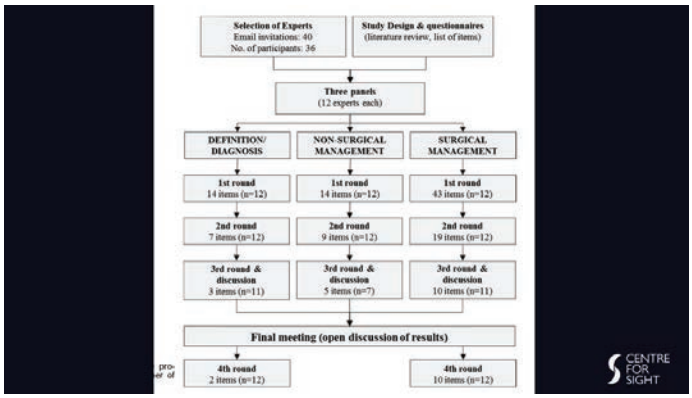

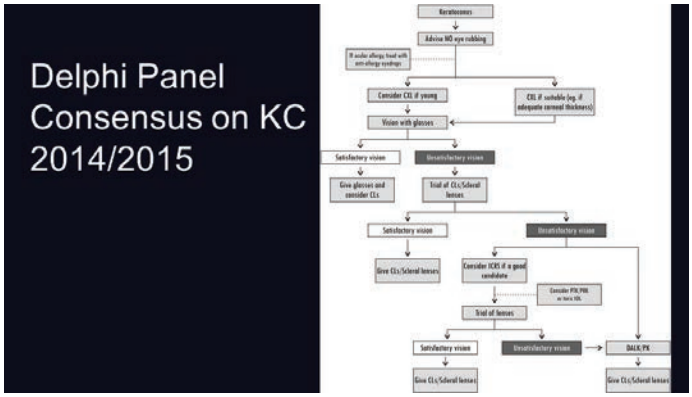

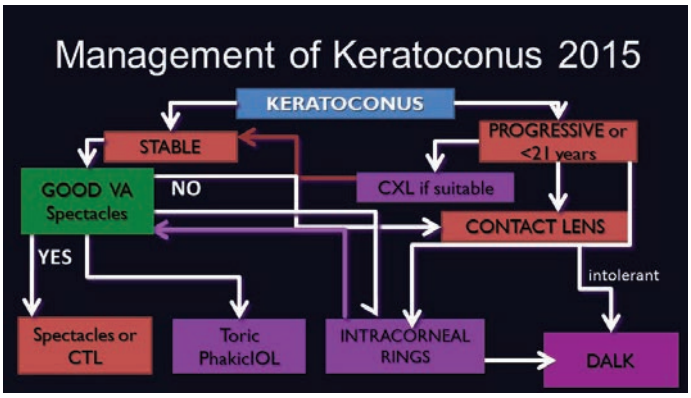

'Kertoconus - An Algorithmic approach'

(slides 1-7)

Sheraz Daya
MD FACP FRCS(Ed) FRCOphth